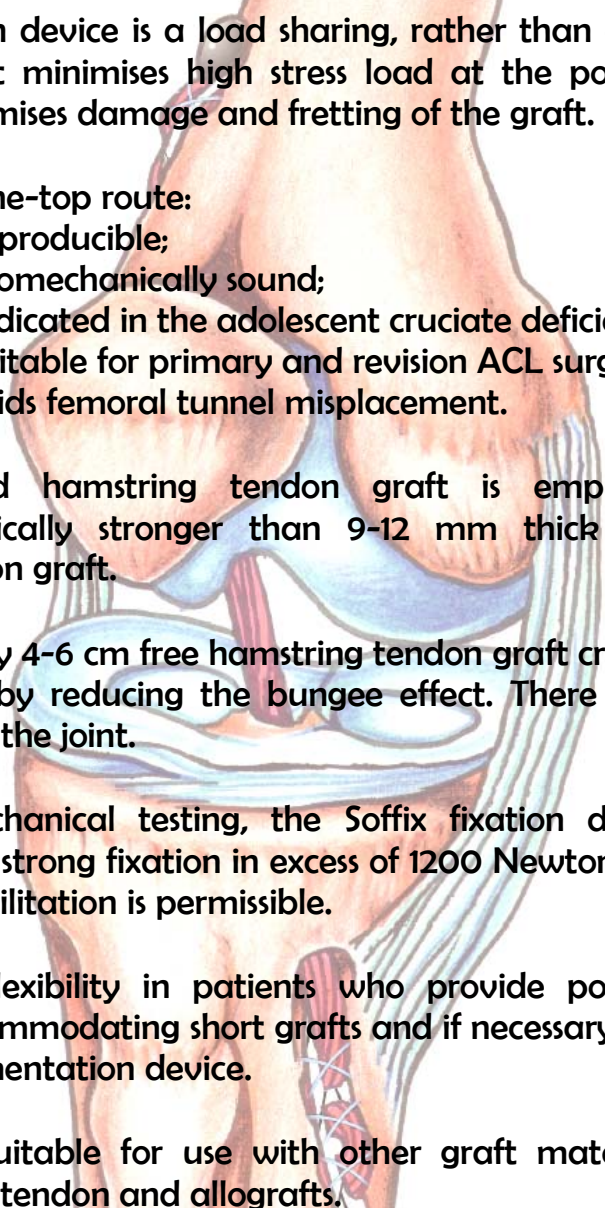


# Buttonhole Soffix

## Surgical Technique

for

### Hamstring Reconstruction of the Anterior Cruciate Ligament

- 
- ✓ The fixation device is a load sharing, rather than a load bearing structure. It minimises high stress load at the point of fixation, which minimises damage and fretting of the graft.
  - ✓ The over-the-top route:
    - is reproducible;
    - is biomechanically sound;
    - is indicated in the adolescent cruciate deficient knee;
    - is suitable for primary and revision ACL surgery;
    - avoids femoral tunnel misplacement.
  - ✓ Four-strand hamstring tendon graft is employed. This is biomechanically stronger than 9-12 mm thick bone-patellar bone-tendon graft.
  - ✓ There is only 4-6 cm free hamstring tendon graft crossing the knee joint, thereby reducing the bungee effect. There is no synthetic material in the joint.
  - ✓ On biomechanical testing, the Soffix fixation device provides immediate strong fixation in excess of 1200 Newton and therefore early rehabilitation is permissible.
  - ✓ It allows flexibility in patients who provide poorly harvested grafts, accommodating short grafts and if necessary it can be used as an augmentation device.
  - ✓ It is also suitable for use with other graft materials including quadriceps tendon and allografts.

# Introduction

---

This document details the operative technique for hamstring reconstruction of the ACL using the Buttonhole Soffix device.

The role of arthroscopy in this procedure can be left to the preferences of the individual surgeon concerned. An arthrotomy is not required and whilst two incisions are necessary to secure proximal 'over-the-top' and distal tibial fixation, the technique is less invasive than current arthroscopic surgical methods as it avoids a femoral tunnel, a notchplasty and preparation of the medial wall of the lateral femoral condyle. It should be emphasised that the Buttonhole Soffix acts as a load sharing device for four-strand hamstring graft, which minimises fretting and damage to the graft.

The technique is flexible and can accommodate different lengths of harvested graft. If the graft harvesting has yielded less than optimal graft length, the central portion of the tape can be retained to augment the construct.

Up to 40% of femoral tunnels are inaccurately sited, even by experienced arthroscopic surgeons. By using a grooved over-the-top proximal femoral placement, this complication is avoided and the graft is sited in an optimal position.

The technique, which is instrument guided, is simpler to perform and more reproducible than current methods.

In four years' clinical experience, the technique has provided results, which are equal to or better than other published series (mean KT-2000 post-operative arthrometric SSD of 2.1 mm).

In addition to primary ACL reconstruction, this technique is particularly useful in the adolescent cruciate deficient knee and revision ACL surgery.

**Mr Michael Mowbray**  
Consultant Orthopaedic Surgeon

# The Buttonhole Soffix Fixation Device

---

The Buttonhole Soffix fixation device consists of a double looped polyester tape. At either end there are three 'buttonholes' in series, separated by strong transverse braiding. This is the site where the hamstring tendons are interwoven and sutured with a non-absorbable suture material, leaving parallel tendon material in the centre of the graft.

The central 4-6cm of the tape are excised after the tendons have been attached, leaving a window of 4-6cm of free tendon material in the centre of the graft complex. It is this portion of the graft-tendon complex that lies in the intra-articular region of the knee joint.

Graft preparation is undertaken on a special frame and once the graft complex has been prepared it is lifted off the frame and is ready for implantation as a single structure.

The graft-tendon complex is of predetermined length and can be preconditioned prior to implantation.

It is recommended that the graft-tendon complex is implanted via a tibial tunnel and brought over the top of the lateral femoral condyle. This is supported by extensive experience with an artificial scaffold, which was subjected to mode of failure analysis. It showed that the over-the-top route produces very little stress on the implant at this site and that with time the fixation at the over-the-top site is extremely robust.

Serial testing on operated knees with the KT2000 arthrometer over a 5 year period has shown that laxity does not develop with time, as is reported in several series where hamstring tendon reconstruction was shown to be at a disadvantage for this complication when compared to reconstruction with Bone-Patellar Tendon-Bone graft. This favourable feature is probably a reflection of the fact that only 4-6cm of hamstring tendon graft are 'free', thereby reducing the 'bungee cord effect', noted in other hamstring reconstructions, where a much longer element of free tendon is employed.

The loops at either end of the Buttonhole Soffix provide the sites for cortical fixation of the device. Polysulphone carbon bollards are recommended for fixation. Once the graft is in situ in the joint and after it has been secured distally, the graft can undergo further pretensioning by flexing and extending the knee joint, whilst tension is applied to the proximal - and as yet unfixed - loop of the graft-tendon complex.

Experience with the polysulphone carbon bollards over 20 twenty years has demonstrated that this method of fixation is extremely secure and very strong, with almost no failures.



Figure 1

# The Surgical Technique

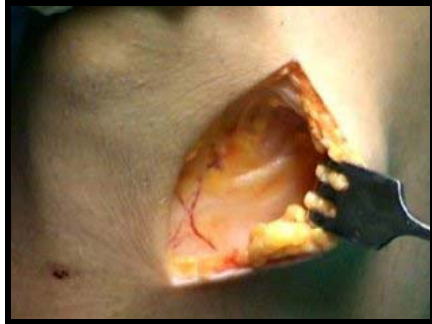

Figure 2

The patient is placed in a supine position on the operating table and both a thigh tourniquet and appropriate sterile drapes are applied.

The affected knee is flexed over the side of the operating table and a four to five centimetres oblique antero-medial incision is made over the origin of the pes anserinus on the upper tibia.

The pes anserinus is cleared of subcutaneous fatty tissue and the upper border of this structure is identified (**Figure 2**).

A thin covering of fascia derived from sartorius is incised vertically across the origin of the pes anserinus and is lifted off the underlying tendons, carrying with it the infrapatellar branch of the saphenous nerve, which is thereby protected from surgical trauma.

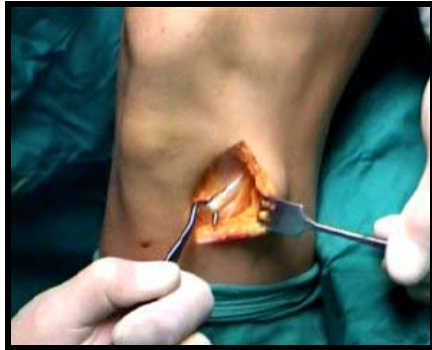

Figure 3

Gracilis and semitendinosus can be clearly identified, both visually and by rolling the tendons under the fingertips (the sleeping policeman's sign). It is easier to identify these tendons by pulling the upper border of the pes anserinus forwards with a blunt hook and identifying the conjoint origin of the tendons from the deep surface of this structure.

The blunt hook is passed first around gracilis and the tendon is freed from surrounding soft tissue connections by blunt and sharp dissection as far proximally as visualisation and palpation will allow (**Figure 3**).

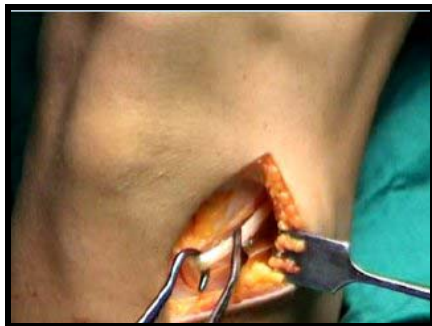

Figure 4

Once the tendon has been freed from the surrounding tissue, tension is applied, either by pulling the tendon over the index finger or a blunt hook. A tendon stripper is applied and advanced in line with the tendon towards its insertion in the groin (**Figure 4**).

The proximal insertion of the tendon is released once the tendon stripper has reached the musculotendinous junction.

The semitendinosus is then identified and the same process of careful dissection is applied. It should be noted that there is a constant inferior band-like connection with semimembranosus, which needs to be identified and divided.

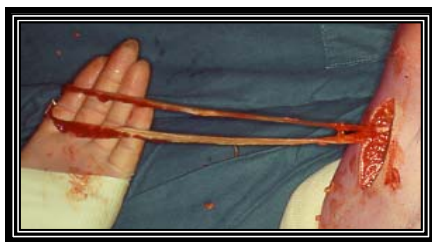

Figure 5

Once the distal attachment of semitendinosus has been mobilised, the tendon stripper is again applied and the graft is harvested as before (**Figure 5**). The conjoint attachment of the two tendons is then detached from the tibial origin to be used later in conjunction with the Buttonhole Suffix as a free graft. Between 20 and 30 centimetres of tendon of varying morphology is usually obtained by this method.



# The Surgical Technique

## Preparation of the Tibial Tunnel

### Assembly of the Rhino Horn Jig

Attach the appropriate left or right hand probe with aiming device to the top of the main shank of the Rhino Horn Jig and lock into position (**Figure 6**).




Figure 6

### Positioning the Rhino Horn Jig within the Knee Joint

With the knee in approximately 60° flexion, pass the offset probe via an anteromedial arthroscopic portal into the joint (**Figure 7**).

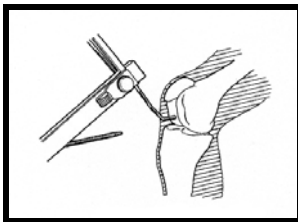


Figure 7

Ensure the Rhino Horn Jig tip has engaged the intercondylar notch and then place the knee in full extension with the foot in neutral.

Arrange the Jig so that its shank is parallel to the long axis of the tibia and the rotating cam rests on the skin over the tibial shaft (**Figures 8, 9, 10**). The cam can then be locked into position.

The offset nature of the probe ensures that the jig is rotated medially by approximately 20°.

The aiming device, which is oriented perpendicular to the mid point of the patellar surface and long axis of the femur, fine tunes this position (**Figure 11**).

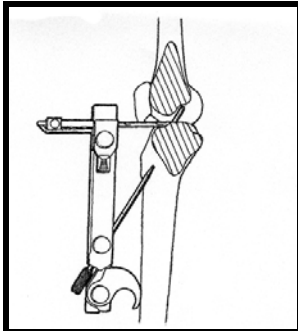


Figure 8

With the knee extended, the shank of the jig is pulled firmly in the direction of the long arm of the aiming device. This ensures that the upturned tip of the probe is centred at the apex and roof of the intercondylar notch.

The geometry of the jig and the probe ensure that the tibial tunnel exits behind the apex and roof of the intercondylar notch when the knee is in extension, thereby avoiding graft impingement. It also ensures that in the sagittal plane the angle of the tunnel is 60° to the long axis of the tibia and in the coronal plane the tunnel is angled approximately 20° medial to lateral. This orientation ensures that the graft follows the anatomical course of the natural ACL and avoids lateral wall impingement in the notch.

**Figure 12** demonstrates the offset nature of the probe, which passes around the medial femoral condyle with the leg in extension.

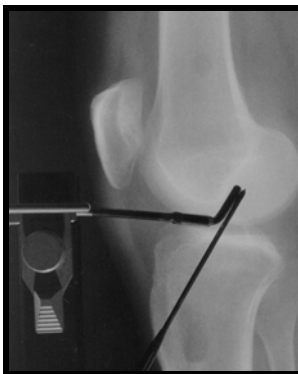

Figure 9

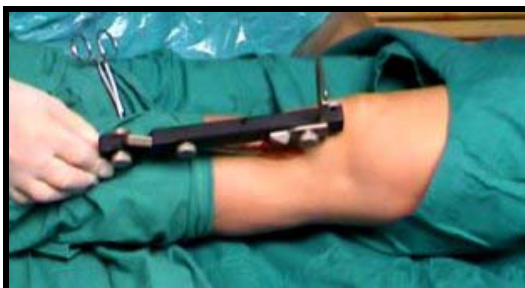

Figure 10

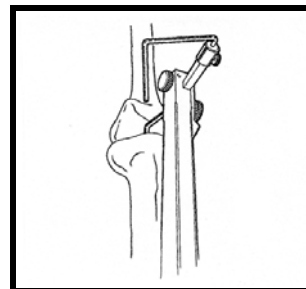


Figure 11

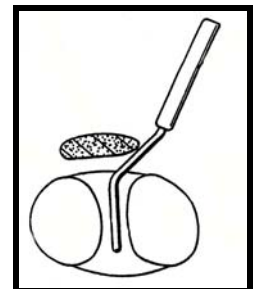


Figure 12

# The Surgical Technique

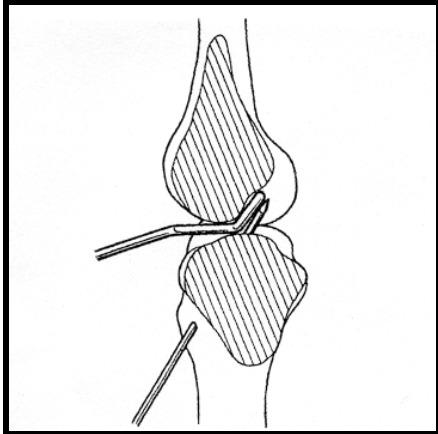


Figure 13

## Drilling the Tibial Tunnel

A drill is passed through the guide wire sleeve hole in the shank of the jig breaching the tibial cortex. This pre-drilling, which defines the appropriate direction of the tibial tunnel, prevents the guide wire, which is passed subsequently, from skidding on the tibial cortex into an eccentric position.

The appropriate length of the guide wire may be predetermined before introducing the jig by passing it through the guide wire sleeve until the tip of the guide wire approximates to the tip of the upturned off set probe (**Figure 6**).

The guide wire sleeve is then passed up through the shank and a guide wire is passed through the sleeve into the predrilled tibial cortex. It is then advanced until it emerges from the tibial articular surface (**Figure 13**).

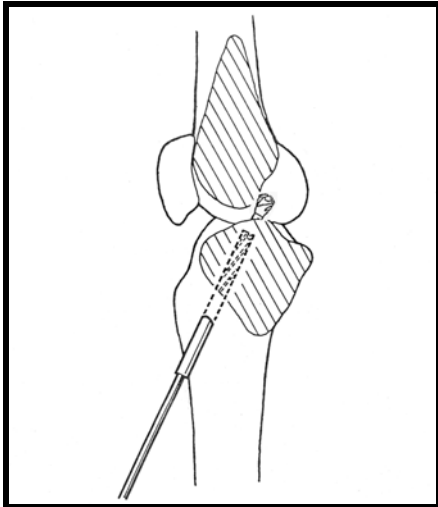


Figure 14

Once the guide wire is in place, the jig and attached probe are removed and the position of the guide wire may be verified arthroscopically.

After the graft diameter has been determined with a sizing tube, the guide wire is over-drilled producing a tibial tunnel of the appropriate diameter. Overdrilling should be avoided (**Figure 14**).

A T-bar probe can be used to double check for impingement with the knee in extension.

## Back Radiusing the Tibial Tunnel Exit

With the knee in approximately 60° degrees of flexion, an appropriate sized Back Radius Cutter (**Figure 15**) (IN542, IN544) is passed into the tibial tunnel, with the cutting blade withdrawn.

Once the tip of the Back Radius Cutter has passed beyond the exit of the tibial tunnel, the cutting blade is engaged and the posterior quadrants of the exit of the drill hole are gently radiused (**Figures 15 & 16**).

The Back Radius Cutter is withdrawn, after retraction of the cutting blade and residual swarf inside the knee is washed out with saline.

The above process ensures a smooth trumpet-shaped tibial tunnel exit, which reduces fretting and abrasion.



Figure 15

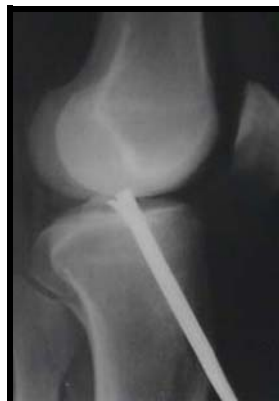

Figure 16

# The Surgical Technique

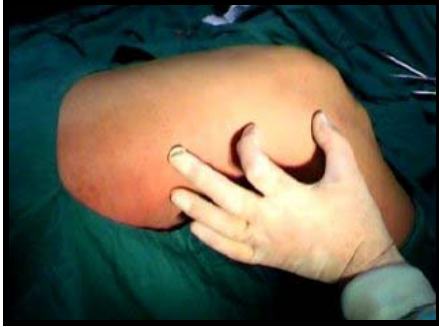

Figure 17

## Preparation of the Over-the-top Route

With the knee in flexion, a 4-5 cm long incision extending proximally from the lateral femoral epicondyle is fashioned. The fascia lata is divided in line with the incision and the underlying vastus lateralis is freed from the lateral intermuscular septum and retracted anteriorly (**Figure 17 & 18a-d**).

The over-the-top route is defined by identifying the superior lateral genicular vessels seen closely applied to the femur, running transversely and perforating the intermuscular septum through a small hiatus.

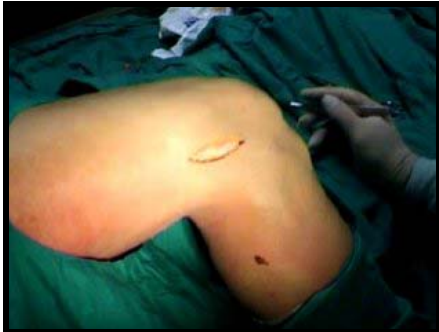

Figure 18a

The hiatus is identified and enlarged with blunt and sharp dissection, until the tip of the index finger can be readily admitted into a space, which lies behind the femur and just above the lateral femoral condyle.

Once this site has been located, the leg is extended and a thin sound or probe is passed up the tibial tunnel towards the over-the-top route. The tip of this probe can be palpated by a finger placed in the proximal wound, overlying the medial border of the lateral femoral condyle.

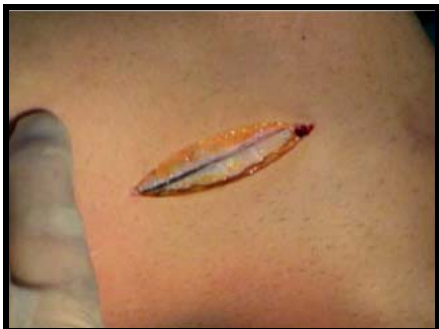

Figure 18b

A rasp with a sharpened, bevelled tip, with a flat rasping surface on one side and a smooth rounded contour on the other side, is used to breach the posterior capsule. A groove is formed at the site of the proximal attachment of the anterior cruciate ligament by pistoning the rasp at the over-the-top site.

A looped wire is passed through the tibial tunnel to the over-the-top position and a similar wire is railroaded back to the exit of the distal tunnel on the tibia in preparation for passage of the graft.

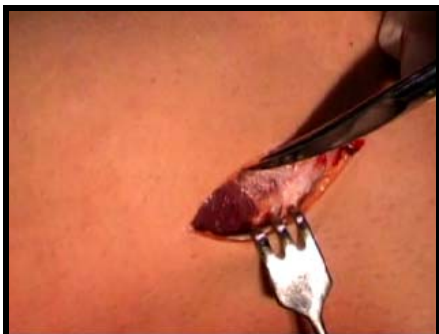

Figure 18c

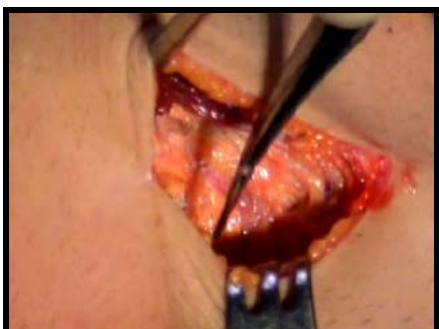

Figure 18d



# The Surgical Technique



Figure 19

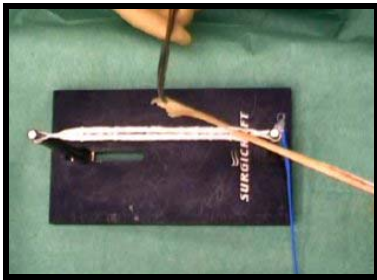

Figure 20

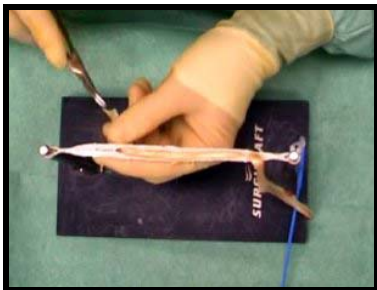


Figure 21



Figure 22

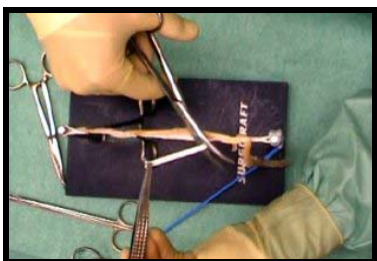


Figure 23

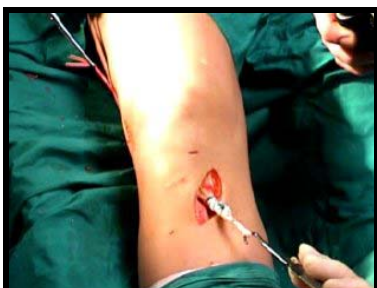


Figure 24

## Preparation of the Buttonhole Soffix Hamstring Construct

The Buttonhole Soffix consists of a braided tape, available in three lengths (15.5, 17 and 18.5 cm). There is a loop at either end to allow fixation to bone with either a bollard or washer and screw. Adjacent to the loops at either end there are three buttonholes in series along the length of the tape separated by cross braiding.

The length of the Buttonhole Soffix required may be predetermined with a colour-coded length gauge.

A Buttonhole Soffix of appropriate length is attached by the loops at either end to a frame, in preparation for reception of the harvested hamstrings (**Figure 19**).

The hamstrings are prepared by removing any surplus muscle and frayed tissue.

One hamstring is passed through the most distal buttonhole at one end of the Buttonhole Soffix with equal lengths of tendon either side of the buttonhole (**Figure 20**).

The free ends are brought towards the opposite end of the Buttonhole Soffix and woven through the three buttonholes (**Figure 21**).

The second tendon is passed through the buttonhole at the opposite end and a similar process of attachment is employed.

The tendons are then sutured to the Buttonhole Soffix using non-absorbable (size 5 gauge polyester) suture material (**Figure 22**).

Once the tendons have been securely attached to the Buttonhole Soffix, the frame is loosened slightly and the central 4 to 6 centimetres of the Soffix tape is cut out with scissors, leaving a central window of free 4-strand hamstring graft (**Figure 23**).

The Buttonhole Soffix hamstring construct, which is of predetermined length may then be removed from the frame and is ready for passage through the knee joint.

The hamstring construct is rail-roaded through the tibial tunnel to the over-the-top position and this is facilitated by a polyester tape passed through loops in the rail-roaded wire and graft (**Figure 24**).

### Manual Preconditioning

Graft preconditioning is undertaken manually after removal of the construct from the preparation frame. Further preconditioning is undertaken when the graft has been placed in the joint and when the distal fixation on the tibia has been completed, but before proximal fixation is undertaken. This is achieved by flexing and extending the knee joint whilst an assistant applies tension to the graft through the proximal wound.



# The Surgical Technique



Figure 25

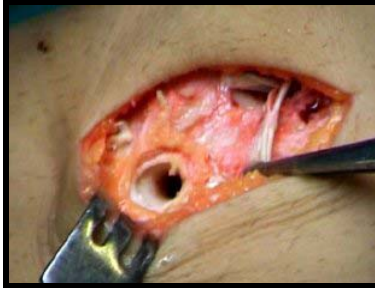


Figure 26

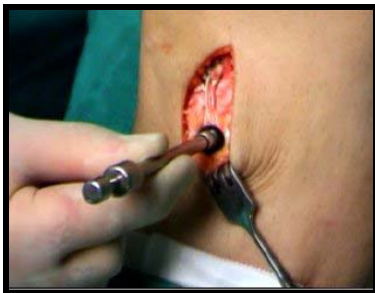

Figure 27

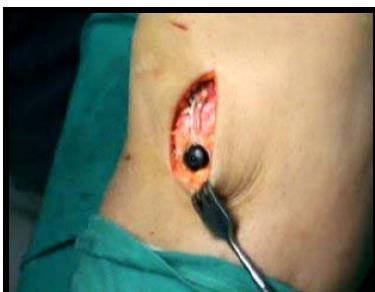

Figure 28



Figure 29

## Fixation of the Buttonhole Soffix

The device is fixed proximally and distally, using either a polysulphone bollard (**Figure 25**) or washers and screws.

When a bollard is used, a unicortical drill hole is prepared with a special drill (**Figure 26**). The bollard is then placed through a loop at either end of the Buttonhole Soffix-tendon complex (**Figure 25**). The bollard is then introduced into the drill hole and is secured by tapping home the expansion pin in the bollard (**Figures 27 & 28**).

The proximal loop is placed through a hand-held bollard punch (**Figure 29**), which is used to tension the construct proximally and at the same time, a mark on the femoral cortex for siting the proximal bollard fixation is obtained by lightly tapping the punch, or alternatively, a cannulated punch and guidewire may be employed.

The ligament is then fixed proximally on the femur with a second bollard, but before the expansion pin is engaged, the stability of the knee is tested clinically. If this is satisfactory, the expansion pin can be deployed. If appropriate stability is not achieved, further proximal re-siting is undertaken.

The wounds are closed in layers with absorbable suture material, according to the surgeon's preference, and appropriate dressings are applied.

**Figures 30 and 31** show typical tibial tunnel orientation after long-term implantation of the hamstring-Soffix complex with an ideal directional orientation in the coronal and the sagittal planes.

## Post Operative Management

When tested, the Buttonhole Soffix-hamstring construct far exceeds the minimum ultimate tensile load of 500 Newtons, which is required for simple activities of daily living. Therefore, early rehabilitation can be safely undertaken.

However, we would recommend that bracing should be continued for six weeks to allow initiation of early biological fixation of the graft, prior to rehabilitation.

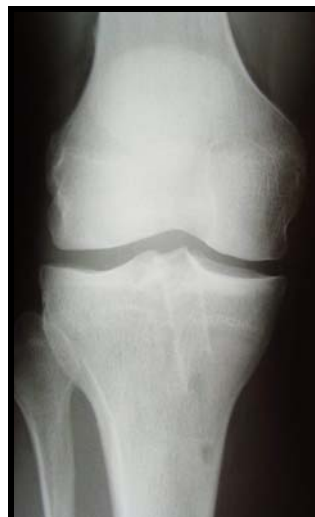

Figure 30

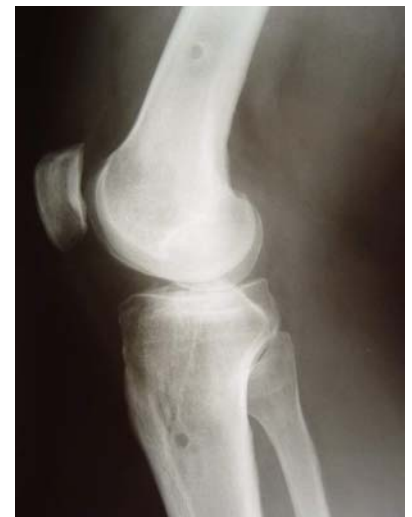

Figure 31

# Bibliography

---

- 1:** Reconstruction of the Anterior Cruciate Ligament: A New Technique of Ligament Placement. Hucker J, Mowbray MAS, Kong KC, McLeod ARM, Strover AE. 4th SICOT Trainees Meeting, Erlangen. Abstract in Proceedings 16-17 April 1993.
- 2:** The Development of Instrumentation for the Reconstruction of the Anterior Cruciate Ligament. McLeod ARM, Kong KC, Mowbray MAS, Strover AE, O'Brien TK, Cooke WD. Technology & Health Care Conference, Amsterdam. Abstract in Proceedings pp 119-120, Faust & Beneken, Elsevier Science 1995.
- 3:** Reconstruction of the Anterior Cruciate Ligament: A New Technique of Ligament Placement. Mowbray MAS, Kong KC, McLeod A, Strover A, Hucker J. Jpn Orthop. Assoc.: 2-3 1993.
- 4:** Mode of Failure Analysis Leading to New Instrumentation for the Enhancement of Cruciate Ligament Reconstructive Surgery. McLeod ARM, Kong KC, Mowbray MAS, Strover AE, Cooke WD, O'Brien TK. XIV Congress of the International Society of Biomechanics, Paris. Abstract Conference Proceedings ISB pp 859-60 1993.
- 5:** New Surgical Technique for Hamstring Tendon Reconstruction of the ACL. Mowbray MAS. Abstract in Proceedings 2nd Pan Arab GCC Orthopaedics Congress UAE Dubai, Oct. 1994.
- 6:** Percutaneous Instrumentation for Anterior Cruciate Ligament Reconstruction. Barry M, Thomas R, Mowbray MAS. Orthopaedic Product News, Oct/Nov 1994.
- 7:** Minimally Invasive Cruciate Ligament Reconstruction. Barry M, Thomas R, Kong KC, Mowbray MAS. Minimally Invasive Th. & Allied Technol. 1996 5: 87-90.
- 8:** Instrumentation to avoid Impingement Lesions in ACL Reconstruction. Barry M, Mowbray MAS et al. The Knee April 1996.
- 9:** The Avoidance of Impingement in ACL Reconstruction. Barry M, Thomas R, Mowbray MAS. JBJS vol 78B, p181, supplement II & III 1996.
- 10:** Soft Tissue Fixation in Autologous Hamstring Reconstruction of the Anterior Cruciate Ligament (ACL). Why Load Bear when you can Load Share? U-Lois JO, Shelton JC, Mowbray MAS. JBJS p171, vol 80B, supplement II 1998.
- 11:** A New Fixation Device for Four Strand Gracilis/Semi-tendinosus Reconstruction of the Anterior Cruciate Ligament. Podmore MD, Verstraten L, Mowbray MAS. JBJS p98, vol 80B, supplement 1998.
- 12:** A Comparison of the Effectiveness of Currently Available Instrumentation for Radiusing Bony Tunnel Exits in Cruciate Ligament Reconstruction. Mowbray MAS, McLeod ARM, Kong KC. The Knee Vol 6, No 1 Jan 1999.
- 13:** Reconstruction of the Anterior Cruciate Ligament of the Knee Joint using an Artificial Ligament - Textbook of Surgical Techniques in Orthopaedics and Traumatology. Mowbray MAS. Elsevier SAS (Paris) 55-540-B-10 2001 5p.
- 14:** Biomechanical Properties of Polyester Mark II Mayday Button Hole and Mark I Suffix acting with young equine and human tendon. Fules PJ, Jadeja HK, Shelton JC, Mowbray MAS. JBJS vol 83B, supplement I: 96 2001.
- 15:** Revision Anterior Cruciate Ligament Reconstruction using Autografts with a Polyester Fixation Device. Fules PJ, Madhav RT, Goddard R, Mowbray MAS. The Knee 2003.
- 16:** Evaluation of Tibial Bone Tunnel Enlargement using MRI Scan Cross-Sectional Area Measurement after Autologous Hamstring Tendon ACL Replacement. The Knee 2003 Mar; 10(1):87-91. Fules PJ, Madhav RT, Goddard RK, Newman-Sanders A, Mowbray MAS. The Knee 2003.
- 17:** Instrument guided semitendinosus-gracilis tendon autograft anterior cruciate ligament replacement technique using a polyester tape and cortical fixation device. Fules PJ, Goddard R, Mowbray MAS. Orthopedics. Accepted for publication 2003.
- 18:** Isometricity and graft placement during anterior cruciate ligament reconstruction. Amis AA, Zavras TD. The Knee 1995 2: 5-17.

# Ordering Information

---

## Buttonhole Soffix Implants

---

AD7155	Hamstring Soffix - 15.5cm
AD7170	Hamstring Soffix - 17cm
AD7185	Hamstring Soffix - 18.5cm

## Fixation Bollards

---

CF460	Fixation Bollard
-------	------------------

## Cruciate Complete Instrumentation

---

IN403	Cannulated Femoral Drill - 8mm
IN404	Cannulated Femoral Drill - 9mm
IN405	Cannulated Femoral Drill - 10mm
IN406	Cannulated Femoral Drill - 11mm
IN512	Straight Rasp
IN515	“Over the top” Hook & Rasp
IN517	Rhino Horn Jig
IN542	Radius Cutter - 6.3mm
IN544	Radius Cutter - 8mm
IN564	Curved Tubular Introducer
IN570	Bollard Drill
IN572	Cannulated Drill - 6.3mm
IN574	Cannulated Drill - 8mm
IN576	Cannulated Drill - 10mm
IN577	Cannulated Drill - 9mm
IN579	Cannulated Drill - 11mm
IN580	Bollard Punch
IN590	Mallet
IN615	Button Drill
IN625	2 x Cannulated Bollard Positioners
IN640	Bone Graft Sizing Gauge - 8.9mm, 10mm and 11mm
IN642	Cannulated Screwdriver - 2.5mm
IN643	Cannulated Screwdriver - 3.5mm
IN644	Hamstring Soffix Suture Frame (contained in own autoclavable case)
IN656	Tendon Stripper
A50024	Sleeve for Rhino Horn Jig

## Length Gauges

---

SI3001	5 x Length Gauges - stiff probe
SI3001/S	1 x Length Gauge - stiff probe
SI3005	5 x Length Gauges - flexible probe
SI3005/S	1 x Length Gauge - flexible probe

## Guide Wires and Fixation Pins

---

IN519/S	1 x Guide Wire for Rhino Horn Jig - 260mm (sterile)
IN520/S	1 x Fixation Pin for Cannulated Bollard Positioner (sterile)
IN522/S	1 x Guide Wire for Rhino Horn Jig - 150mm (sterile)
IN523/S	1 x Guide Wire for Interference Screw (sterile)
IN519	6 x Guide Wires for Rhino Horn Jig, 260mm (sterile)
IN520	5 x Fixation Pins for Cannulated Bollard Positioner (non-sterile)
IN522	6 x Guide Wires for Rhino Horn Jig, 150mm (non-sterile)
IN523	5 x Guide Wires for Interference Screw (non-sterile)
IN600	2 x Lead Wires for PCL Jig (sterile)

## Instrument Sets

---

CCKN10	Set of instruments in autoclavable case
CCKN40	Set of instruments in autoclavable case - for sale or return


# Acknowledgements

---

The Buttonhole Soffix Ligament and Tendon Repair System has been developed in conjunction with Mr MAS Mowbray of Mayday University Hospital, London. We are grateful to Messrs MAS Mowbray MSc MS FRCS, RK Goddard MB ChB MRCS, PJ Fules M.D. and CK Yiannakopoulos M.D. for the preparation of this technical manual.

Only the highest quality medical grade materials are employed in the manufacture of the Surgicraft Buttonhole Soffix System. As an integral part of our Quality Audit System, each stage and process of manufacture is monitored to ensure the highest possible standards. Packaging materials are specially selected and labelled to indicate contents and batch number. Sterilisation is by Gamma irradiation, full irradiation details are noted on each package.

- DHSS Registration No. RO195/SP/01
- Intellectual property Rights are issued worldwide
- In line with our policy of continuous development, we reserve the right to alter designs, illustrations or descriptions without prior notice.
- Worldwide patents apply

CE0086 

To the best of our knowledge, the information contained herein is accurate. However, Surgicraft Ltd cannot accept liability of any kind for the accuracy or completeness of thereof. Final determination of the suitability of the information, the material for the use contemplated and of the manner of this and whether the suggested use infringes any patents is the sole responsibility of the user.

**Caution** (US only)  
Federal law restricts this device to sale by or on the order of physician only.

RM02119 2

**Surgicraft Ltd**  
16 The Oaks, Clews Road  
Redditch,  
Worcestershire  
B98 7ST  
United Kingdom

*Tel:* 01527 551155  
*Fax:* 01527 551166  
*Email:* info@surgicraft.co.uk

Distributed by: