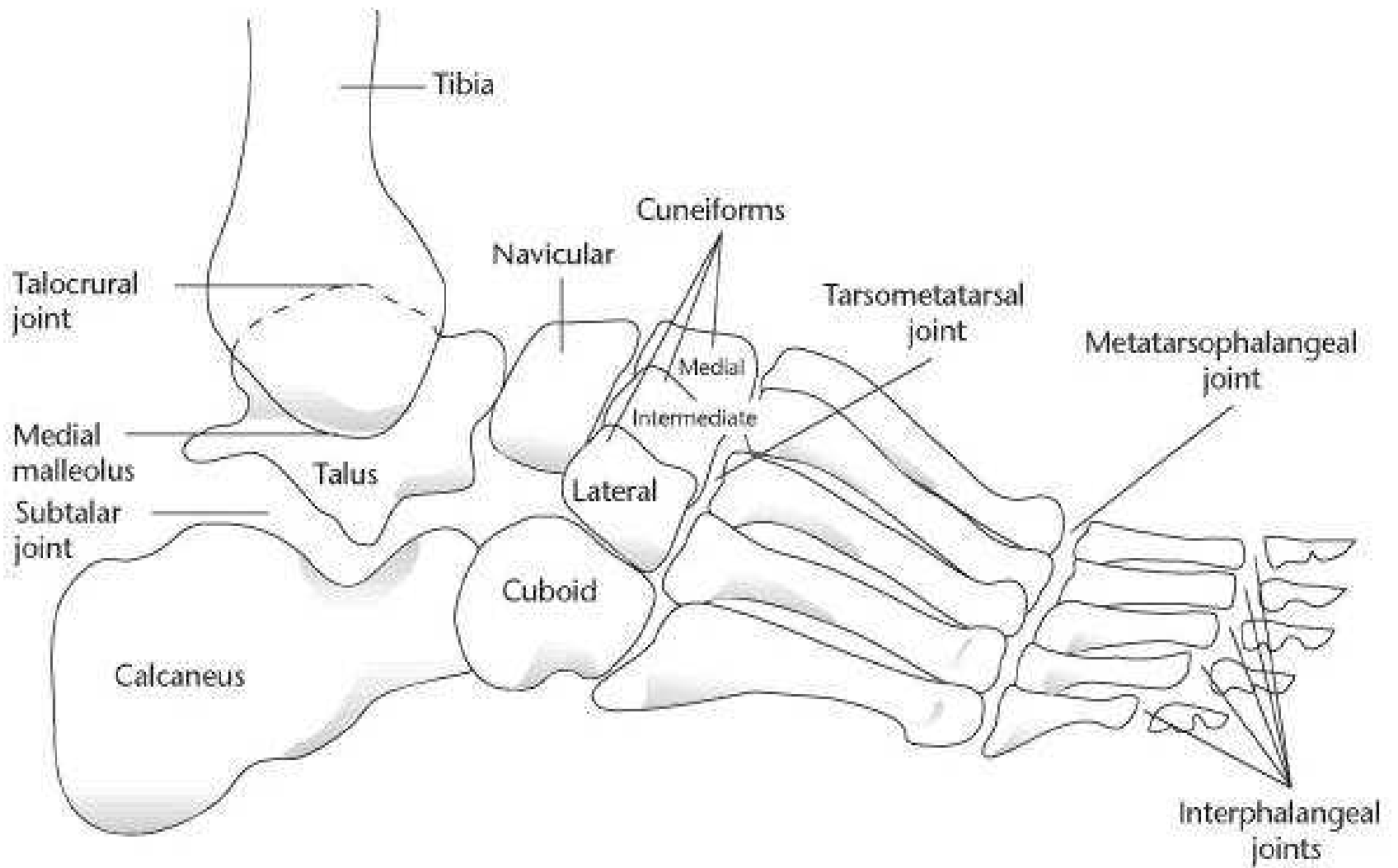
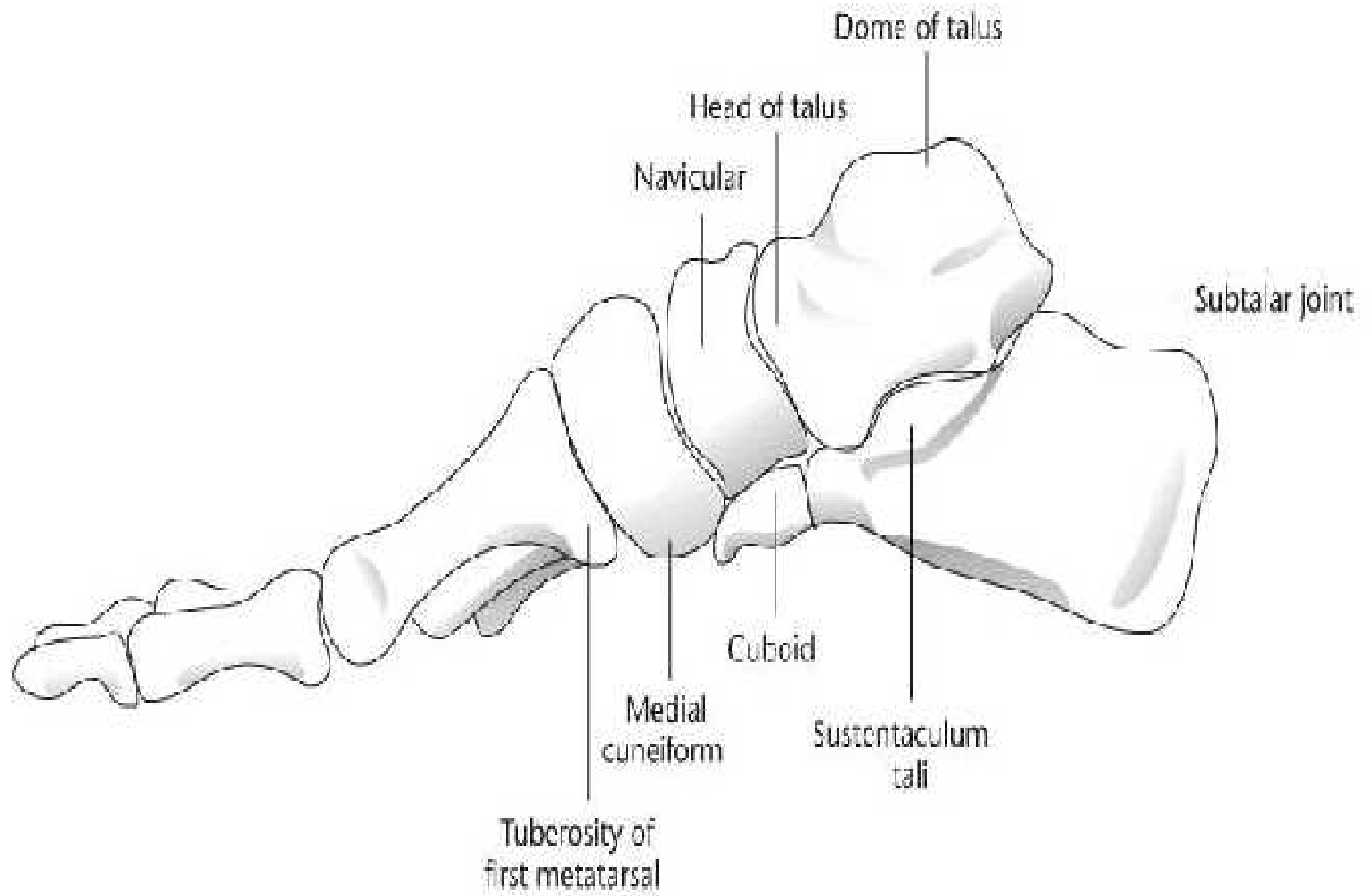


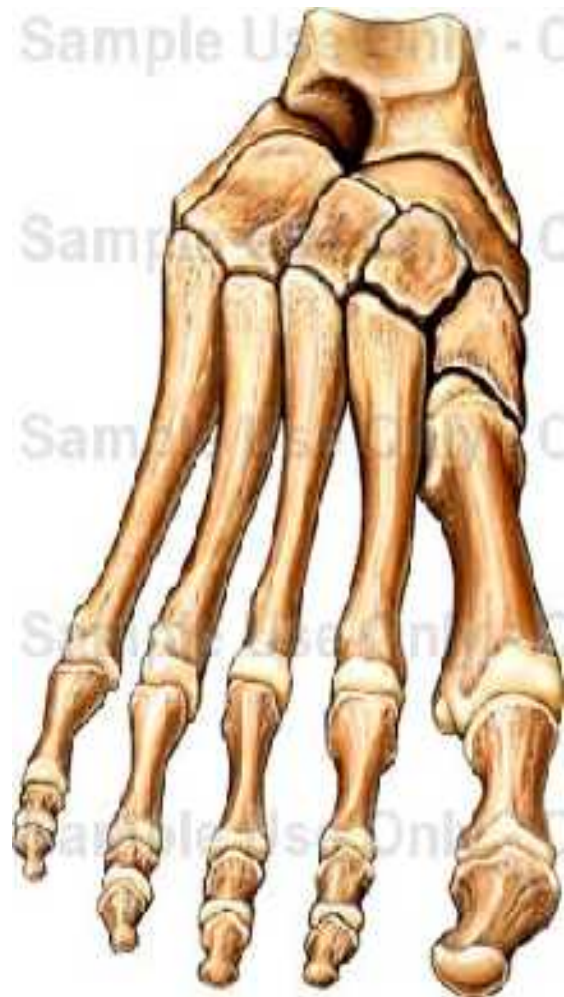The Foot

Bones of the foot

- There are 26 bones of the foot
 - Talus
 - Calcaneus
 - Navicular
 - Cuboid
 - 3 cuneiforms
 - 5 metatarsals
 - 14 phalanges







Arches

- Two arches
 - **Longitudinal** – arch starts at the weight bearing surface of the calcaneus and ends at the metatarsal heads
 - Supported intrinsically by the plantar calcaneonavicular ligament (spring ligament)
 - Talus is also supported by the plantar fascia (which runs from the calcaneal tuberosity to the phalanges
 - Extrinsic support comes from the anterior tibial tendon pulling on its insertion at the first cuneiform and from the posterior tibial tendon and peroneus longus tendon that pass under the foot

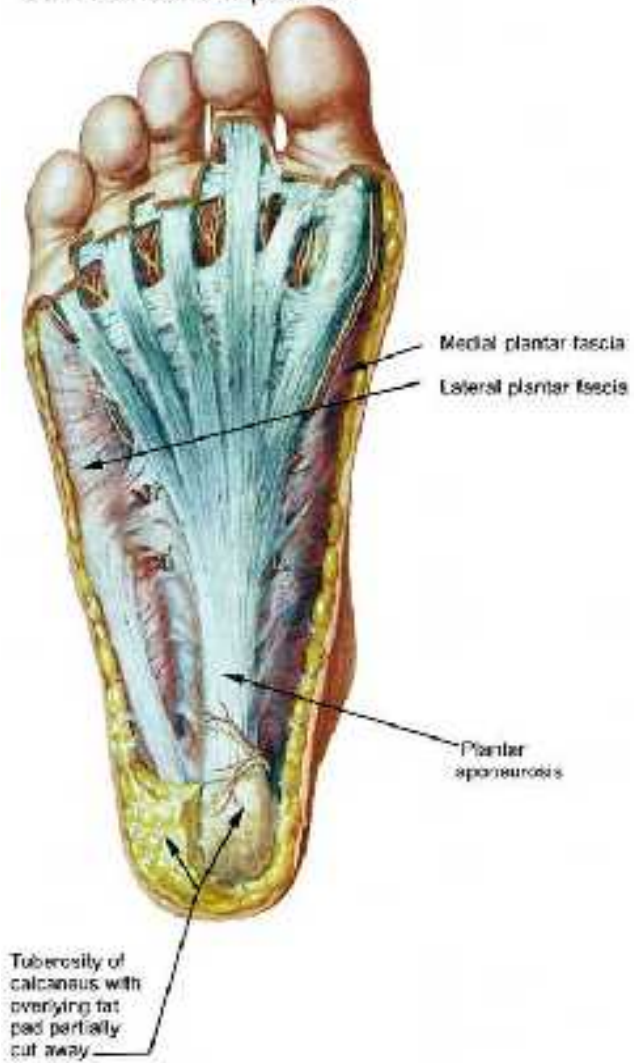
Arches

- Two arches
 - **Transverse arch**
 - The metatarsal bones form a transverse arch when the foot is non-weight bearing and at rest
 - There is no transverse arch at the metatarsal heads on weight bearing, as each of the lateral four metatarsal heads bears one-sixth of the body weight and the first metatarsal head bears two-sixths of the body weight

Dorsalis pedis pulse

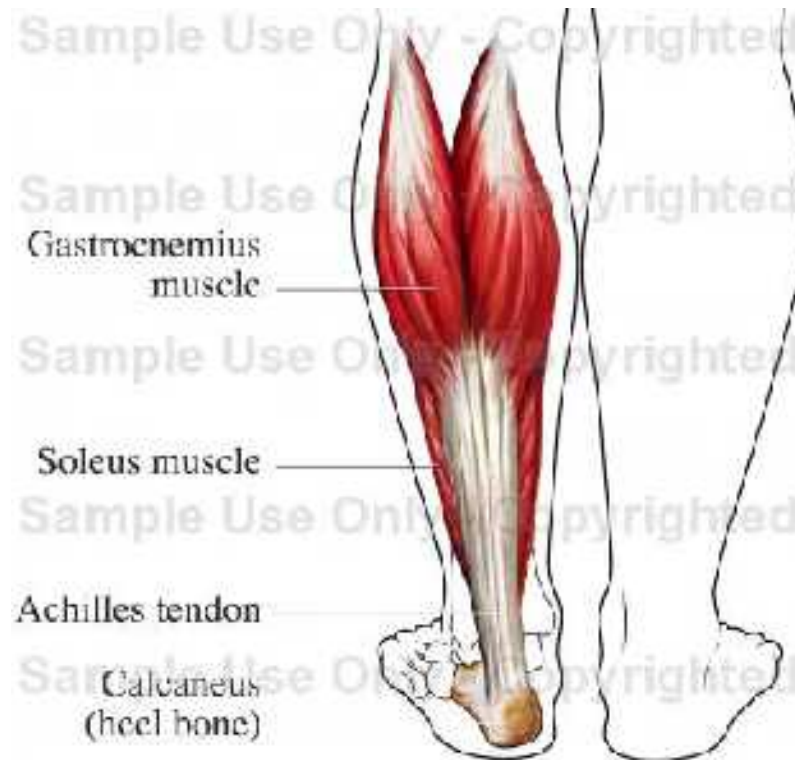- "The dorsalis pedis pulse is best felt by dorsiflexion of the foot. The dorsalis pedis [artery](#) passes along a line from the extensor retinaculum of the ankle to a point just lateral to the extensor tendon of the great toe."

Subcutaneous exposure



Muscles of the foot

- Posterior compartment
 - **Achilles tendon/soleus** – Plantar flexion of the ankle



Muscles of the foot

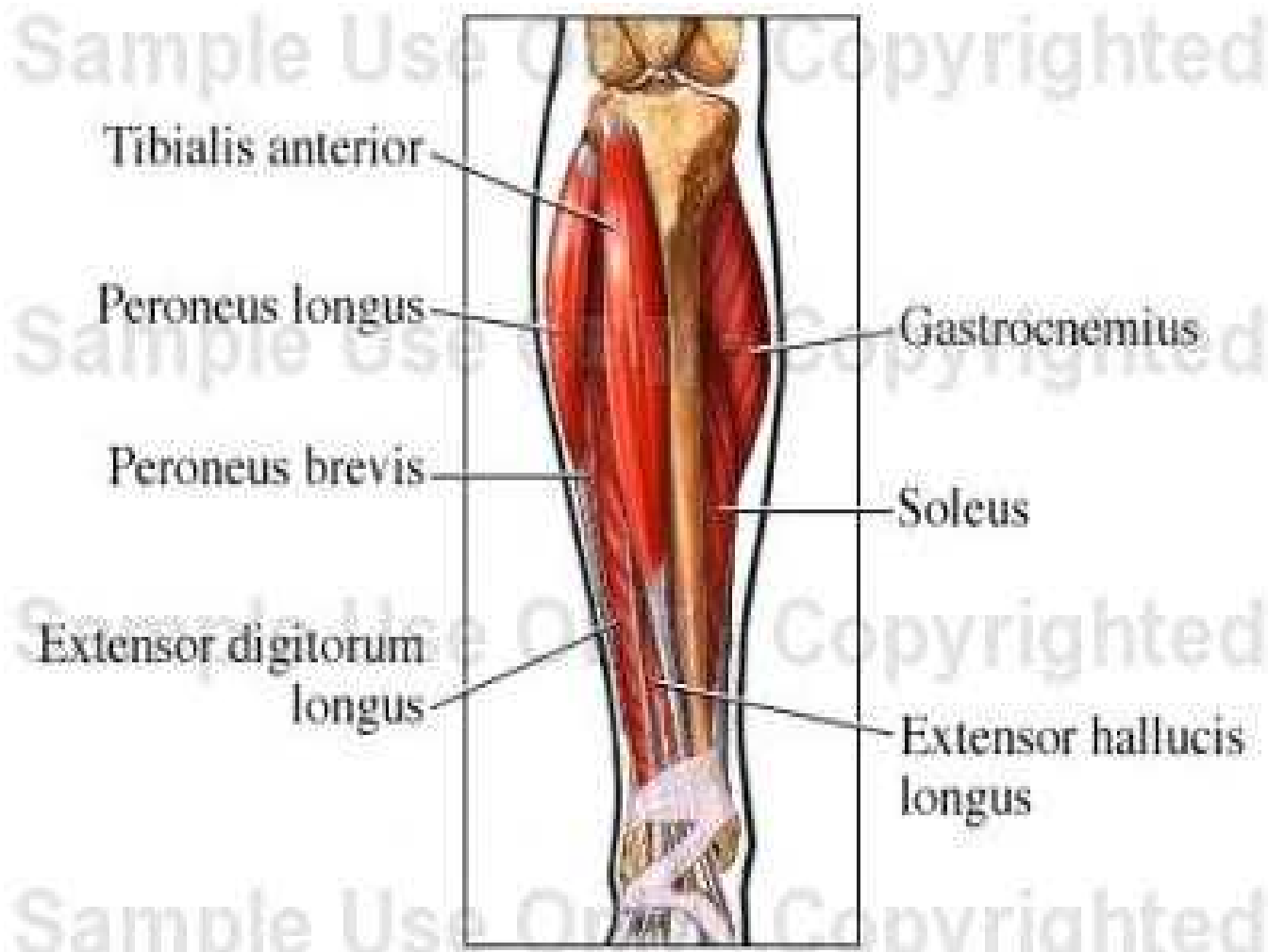
- **Tibialis posterior** – Supports the longitudinal arch and inverts the foot
- **Flexor Digitorum longus** – flexes the lateral four toes
- **Flexor hallucis longus** – flexes the great toe

Muscles of the foot

- Lateral Compartment
 - **Peroneus longus** – Evert and plantar flex the foot
 - **Peroneus brevis** – Evert and plantar flex the foot

Muscles of the foot

- Anterior Compartment
 - **Tibialis anterior** - Dorsal flexion of the ankle, inversion of the foot
 - **Extensor digitorum longus** –Extension of the lesser toes, dorsiflexion of the ankle, eversion of the foot
 - **Extensor hallucis longus** – Dorsiflexion of the ankle, extension of the great toe, weak inversion of the foot
 - **Peroneus tertius** –Dorsal flexion of the ankle, eversion of the foot



Tibialis anterior

Peroneus longus

Peroneus brevis

Extensor digitorum
longus

Gastrocnemius

Soleus

Extensor hallucis
longus

Intrinsic foot muscles

- Intrinsic muscles of the foot are primarily related to toe function
 - Extensor digitorum brevis – short toe extension
 - There are 15 small muscles on the plantar surface of the foot arranged in layers

The fat pad

- The fat pad is a specialized soft tissue structure designed specifically for weight bearing and absorbing impact. It is located between the plantar skin and the underlying calcaneus and plantar fascia

Gait

- The major difference between running and walking is that in the support phase in walking one foot is always on the ground, whereas in running there is an airborne period where neither foot is in contact with the ground

Walking

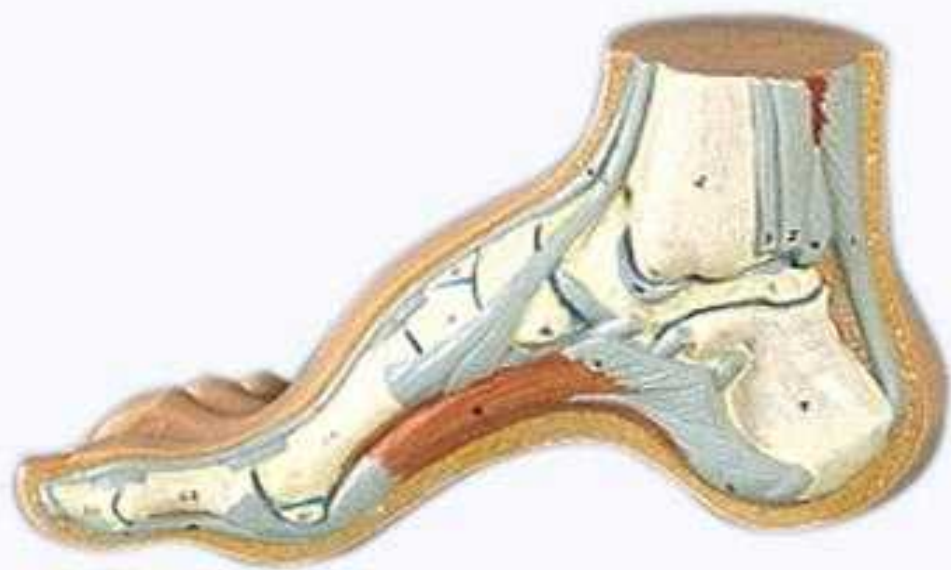- **Initial contact (HEEL STRIKE)** – made with the calcaneus, all the weight-bearing force is absorbed initially by heel contact
- **Midsupport phase (midstance)** – Weight bearing force passes along the lateral border of the foot to the metatarsal heads
 - As this occurs, the normal foot is inverted at heel strike and then pronates (rolls inward) as the weight passes from the lateral side of the foot and is spread out along the entire longitudinal arch
- **Toe off** – the other foot then goes through the identical activity

Running

- The same activity occurs during midsupport, or midstance, phase until toe off
- During toe off phase the gastrocnemius-soleus muscle group forcefully contracts to assist as the runner enters the airborne phase

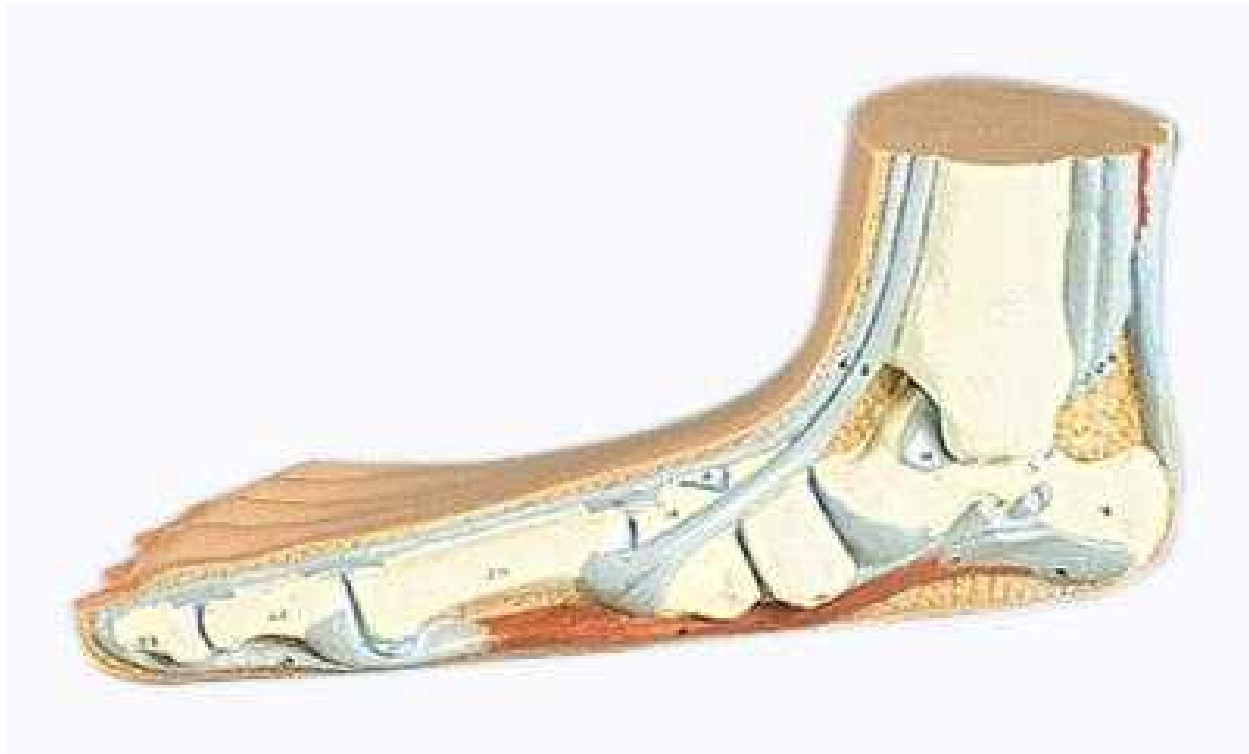Deformities and diseases

- **Cavus foot** – an excessively high longitudinal arch
 - May range from an elevated longitudinal arch to a full-blown deformity, consisting of a varus heel and clawing of the toes
 - Athletes with cavus feet frequently complain of plantar fascia pain due to the tripod effect of the deformity and the increased bow-string pull of the fascia



Deformity and disease

- **Flat foot (Pes Planus)** – is pronated with a flattened longitudinal arch, hindfoot may be in valgus
 - Flexible flat foot (pronated foot) has full range of motion in the midtarsal joint.
 - Rigid flat foot has a fixed deformity, and the flattening of the longitudinal arch is unchanged by dynamic extrinsic input to the foot



Deformity and disease

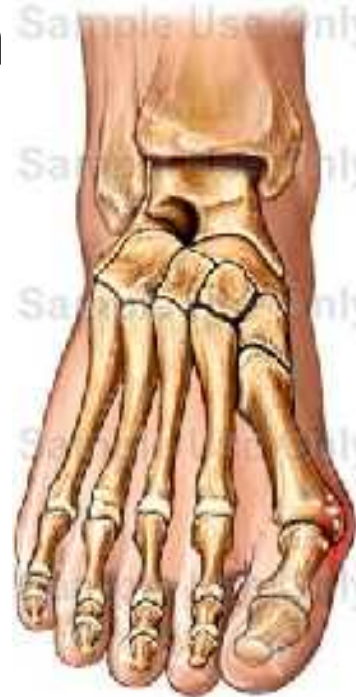- **Metatarsus Varus (metatarsus adductus)** – a congenital deformity of the forefoot, in which the forefoot is angulated and rotated medially in relation to the hindfoot
- **Metatarsus valgus (metatarsus abductus)** – is the opposite deformity of the forefoot, in which abnormal stress is placed on the foot, resulting in painful callosities

Deformity and disease

- **Morton's foot** – Characterized by a short first metatarsal.
 - Excessive weight bearing is then shifted to the relatively elongated second toe, causing an imbalance in the transverse metatarsal arch
 - Interferes with the normal weight-bearing stresses in the forefoot and places greater stress in the forefoot and places greater stress on the second metatarsal head

Deformity and disease

- **Hallux Valgus (Bunions)** – a widening between the first and second metatarsal bones produces a prominence of the first metatarsal head media

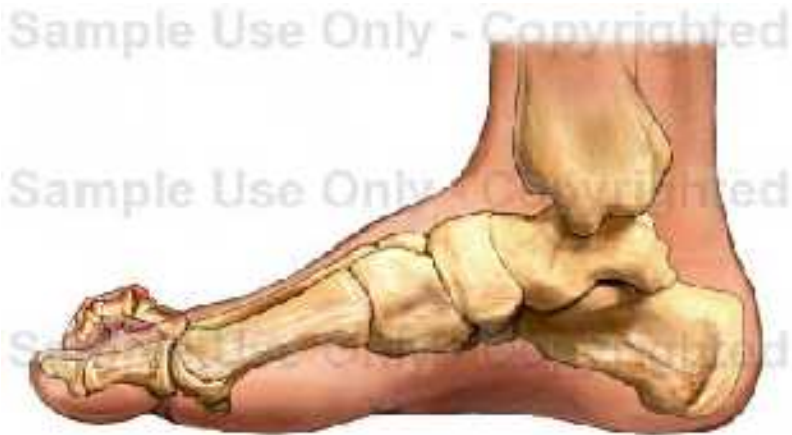

Bunions

- <http://www.livestrong.com/video/2078-bunions-h>

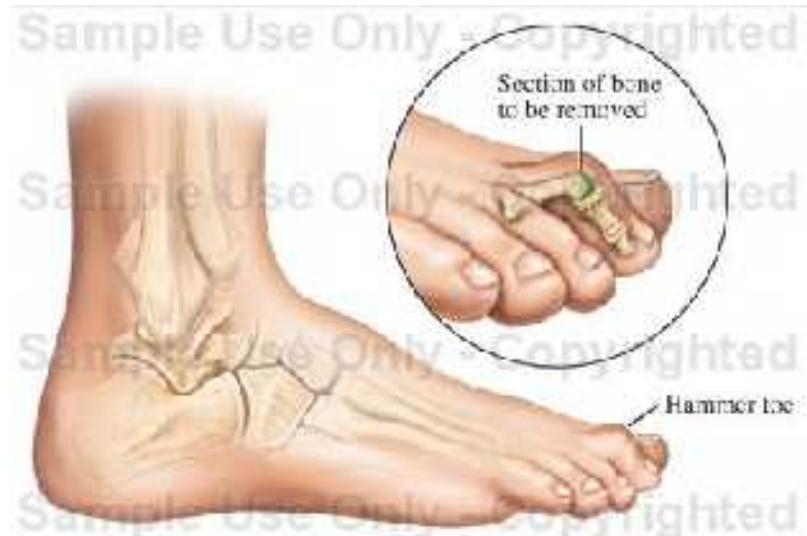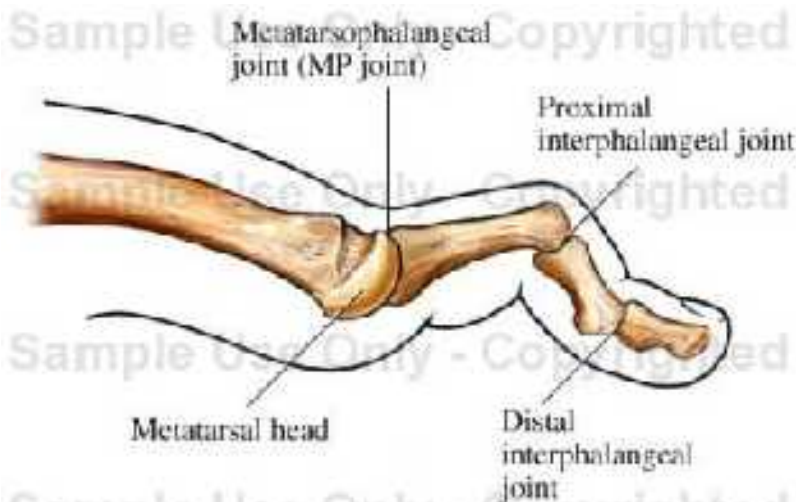
Deformity and disease

- **Claw toes** – hyperextension of the MP joint and a hyperflexion of the IP joint
 - Painful calluses often develop on the dorsum of the IP joints from pressure against the shoe and under the metatarsal heads where they press against the sole of the shoe.



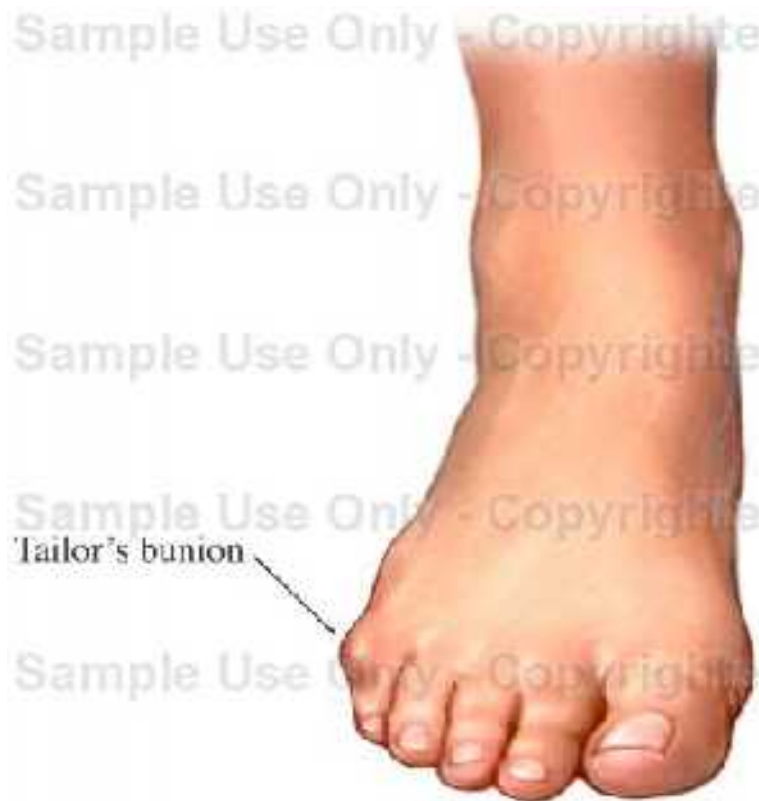Deformity and disease

- **Hammertoes** – deformity of flexion of the distal IP joint, resulting in pressure on the nail and the end of the toe from contact against the sole of the shoe.



Deformity and disease

- **Bunionette (Tailor's Bunion)** – prominence of the lateral aspect of the fifth metatarsal



Deformity and disease

- **Avascular Necrosis** – certain bones in the body have the tendency to lose a portion of their blood supply, and consequently, become nonviable
 - **Freiberg's disease** – a specific avascular necrosis that occurs in the head of the second metatarsal in some adolescents

Deformity and disease

- **Plantars warts** – a skin growth caused by a localized viral infection

Soft tissue injuries

- **Blisters**
- **Calluses**
- **Bursitis** – inflammation of the bursa sac (bursa is a flattened synovial sac that may be located over bony prominences throughout the body)
- **Neuritis** – inflammation or irritation of a nerve

Corns and Calluses

- <http://www.livestrong.com/video/2070-corns-call>

Nail fungus

- <http://www.livestrong.com/video/2074-nail-fungus>

Ingrown toenails

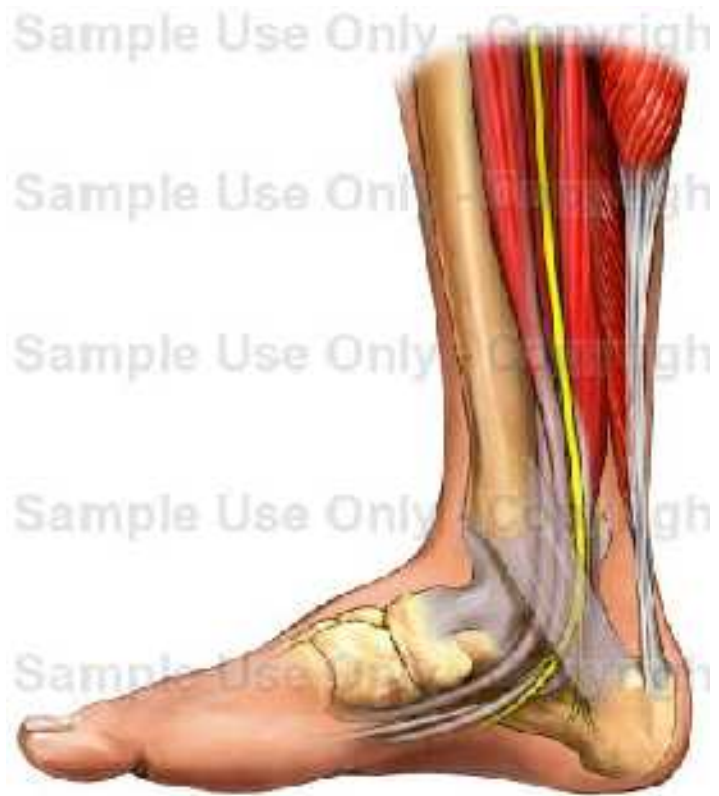- <http://www.livestrong.com/video/2072-ingrown-t>

Soft tissue injuries

- **Morton's neuroma** – common neuritis, is classically characterized by localized pain between the third and fourth metatarsal heads that often radiates into the third and fourth toes.

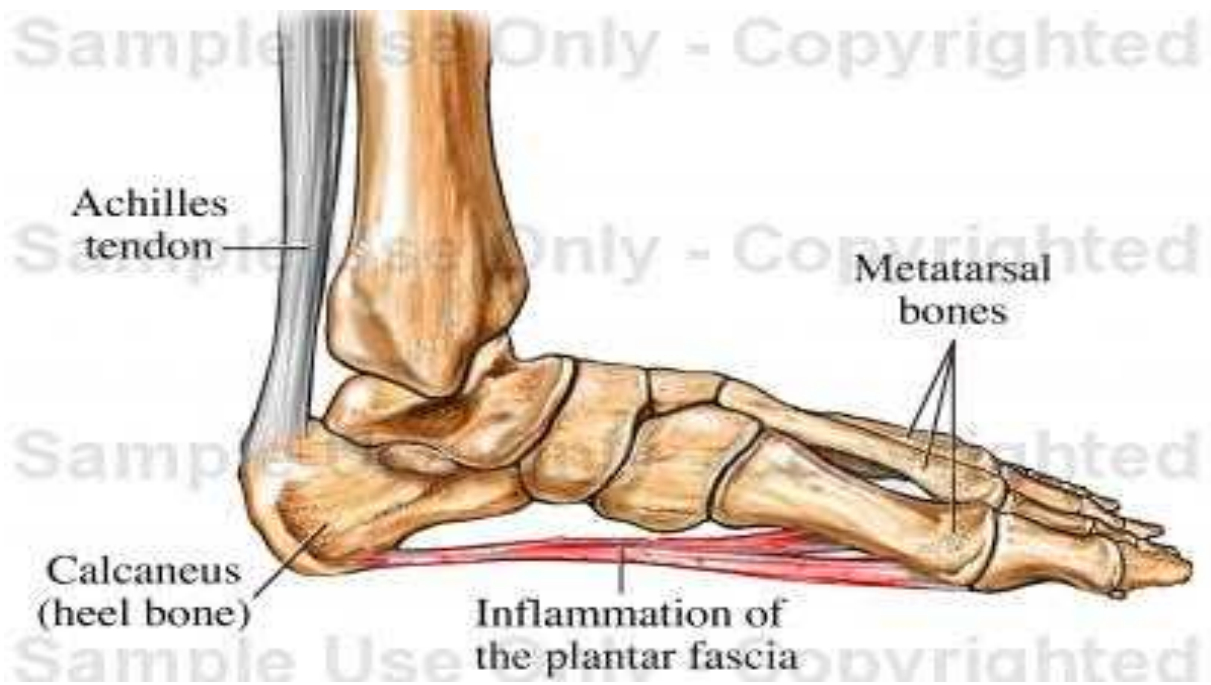
Soft tissue injuries

- **Tarsal tunnel syndrome** – the posterior tibial nerve passes through a soft tissue tunnel behind the medial malleolus to enter the foot, the nerve may become inflamed from pronation or direct trauma, causing swelling and increased pressure in this area



Soft tissue injury

- **Fasciitis** –
 - Plantar fascia is a dense fibrous tissue that runs from the calcaneal tuberosity along the plantar surface of the foot and inserts on the plantar aspect of the metatarsal heads.
 - Plantar fasciitis – inflammation of the fascia from overuse, par



Plantar-fasciitis

- <http://www.livestrong.com/video/2102-plantar-fa>

Soft tissue injury

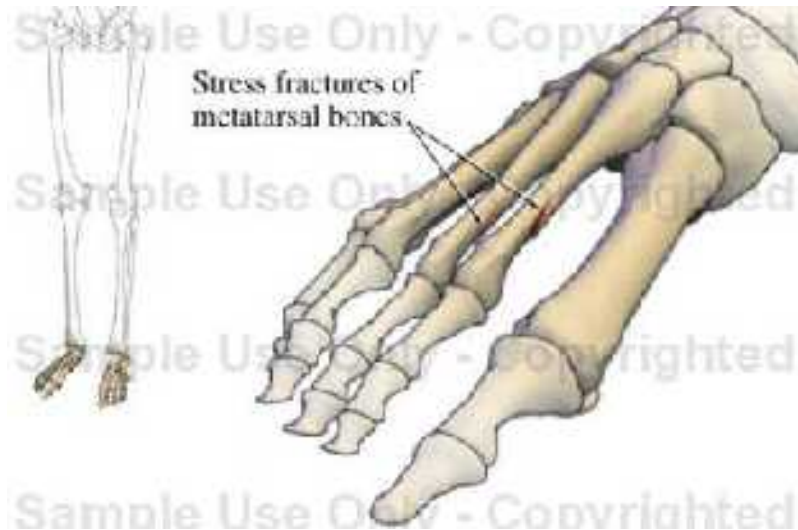
- **Heel bruise (stone bruise)** – direct trauma to the heel pad resulting in a contused heel
- **Sprains** – usually occur in the foot without associated bony injury (commonly involves the ligaments and/or capsule about the calcaneocuboid joint, the sinus tarsi, the metatarsal joints, and occasionally the transverse and longitudinal arches)

Soft tissue injury

- **Sesamoiditis** – an inflammation of the sesamoid bones of the great toe and their encasing fibrous tissues

Soft tissue injury

- **Stress fractures (fatigue fractures)** – stress fractures of the lower extremity are related to overuse and are often seen in long-distance runners

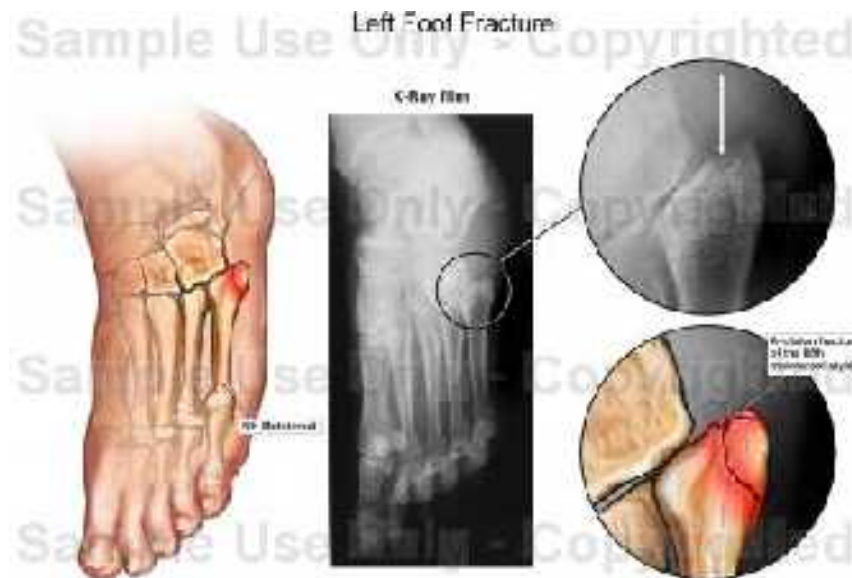


Stress fractures

- <http://www.livestrong.com/video/3647-stress-fra>

Soft tissue injury

- **Avulsion fractures** – common to the base of the fifth metatarsal. Inversion is often the mechanism of injury, creating the overpull of the peroneus brevis muscle, which fractures the bone at the tendinous insertion

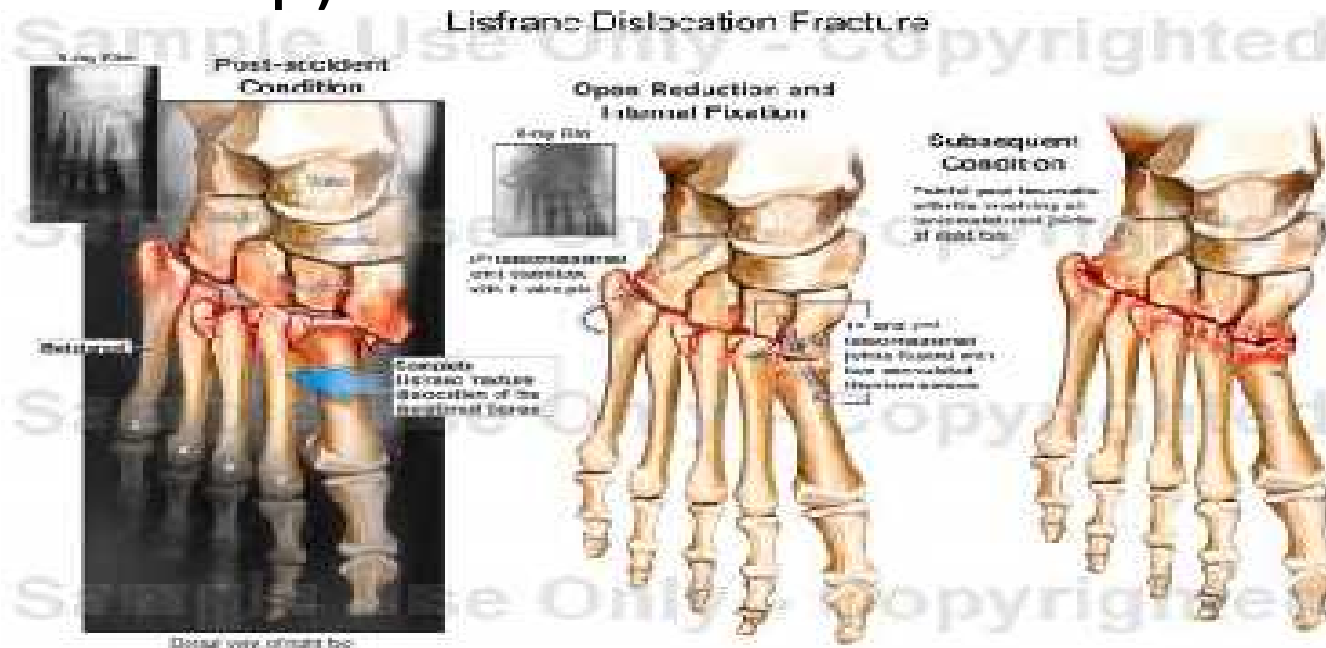


Soft tissue injury

- **Jones fracture** – transverse fractures in the proximal shaft of the fifth metatarsal, occur at a stress site and manifest during an overload trauma

Soft tissue injury

- **Lisfranc fracture** - a rare but severe fracture-dislocation (eversion injury that occurs when a rider is dragged with his or her foot caught in the stirrup)



Lisfranc fracture

- <http://www.livestrong.com/video/3619-lisfranc-jc>

Metatarsal fractures

- <http://www.livestrong.com/video/3624-metatarsa>

Soft tissue injury

- **Turf toe** – a hyperextension injury, with partial tearing of the joint capsule, usually corrected by rest and protective taping

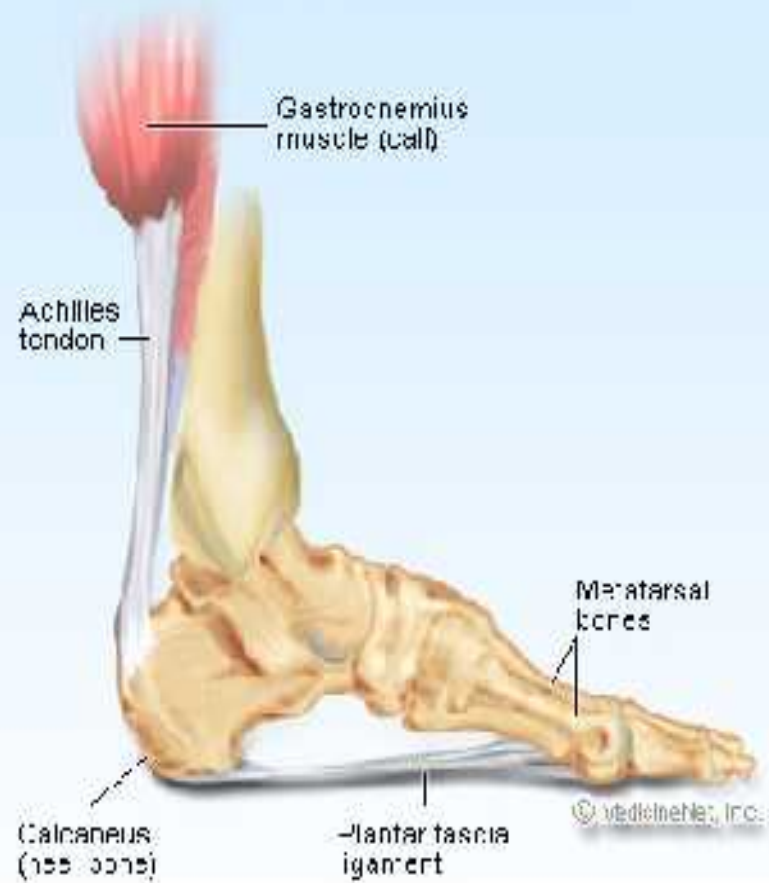Turf toe

- <http://www.livestrong.com/video/3654-turf-toe-h>

Soft tissue injuries

- **Heel Spurs** - A heel spur is a pointed bony outgrowth of the bone of the heel (the calcaneus bone). They are attributed to local **inflammation** at the insertion of soft tissue tendons or **fascia** in the area. Heel spurs can be located at the back of the heel or under the heel, beneath the sole of the foot. Heel spurs at the back of the heel are frequently associated with inflammation of the **Achilles tendon** (**tendinitis**) and cause tenderness and **pain** at the back of the heel made worse while pushing off the ball of the foot.

Achilles Tendon



Heel spurs

- <http://www.livestrong.com/video/2071-heel-spur>

Soft tissue injury

- **Pump Bump (Haglund's deformity)** - is a bony enlargement on the back of the heel that most often leads to painful bursitis, which is an inflammation of the bursa (a fluid-filled sac between the tendon and bone). In Haglund's deformity, the soft tissue near the Achilles tendon becomes irritated when the bony enlargement rubs against shoes.

Con.

- Haglund's deformity is often called "pump bump" because the rigid backs of pump-style shoes can create pressure that aggravates the enlargement when walking. In fact, the deformity is most common in young women who wear pumps.
- To some extent, heredity plays a role in Haglund's deformity. People can inherit a type of foot structure that makes them prone to developing this condition.