

Ankle Anatomy and Exam

Goals and Objectives

- **Better understand the prevalence of ankle injuries in athletics and its long term sequelae.**
- **Review the functional anatomy of the ankle.**
- **Review the clinical ankle exam and how to classify ankle sprains.**
- **Briefly discuss treatment of an acute ankle sprain.**

Ankle Injury: What's the problem?

- **Lateral ligament sprains**

- the most frequent injury sustained by athletes
- constitute 5-24% of all injuries sustained in an individual sport
- produce 25% of all time loss due to an injury in football, b-ball, and CC

- **Lateral ligaments sprains**

- account for 85% of grade-III ankle sprains
- greater than 40% can potentially progress to chronic problems

Long term Sequelae of Sprains

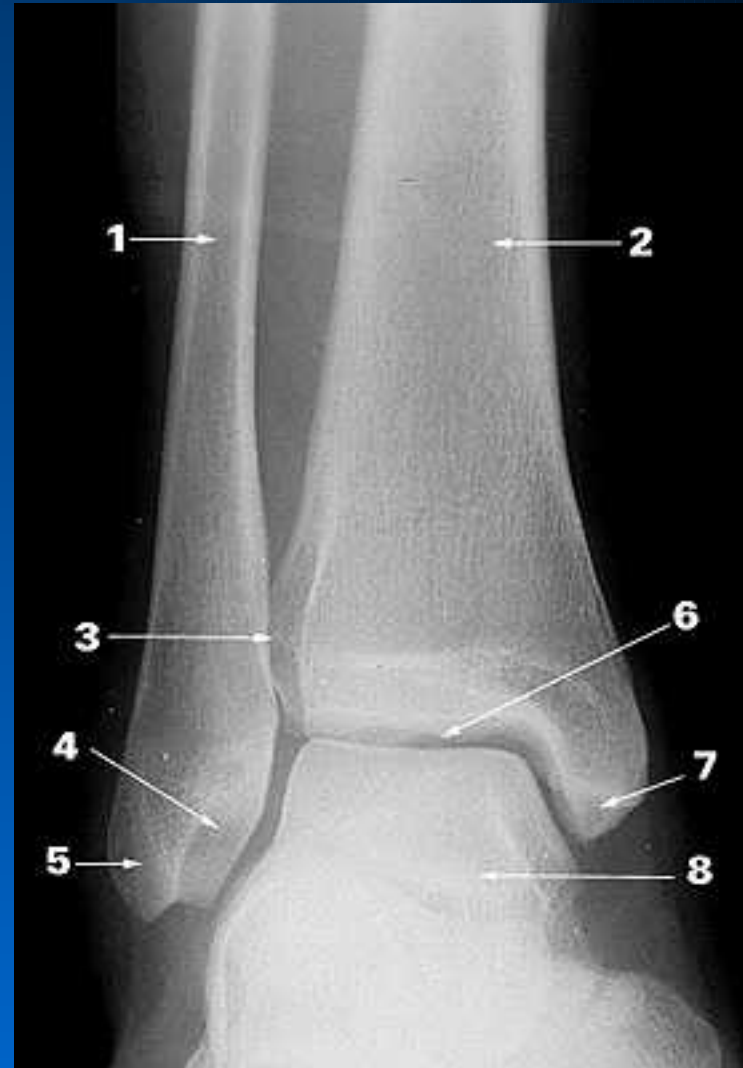- Functional instability and loss of normal ankle kinematics as a complication of ankle sprains may lead to chronic recurrent injury and early degenerative changes.
- Talar displacement of greater than 1mm reduces the ankle's weight-bearing surface by 42%

Ankle Anatomy 101

- **Review the following structures of the ankle joint**
 - **Osseous structures (bones)**
 - **Ligamentous structures**
 - **Tendons/muscles around the ankle**

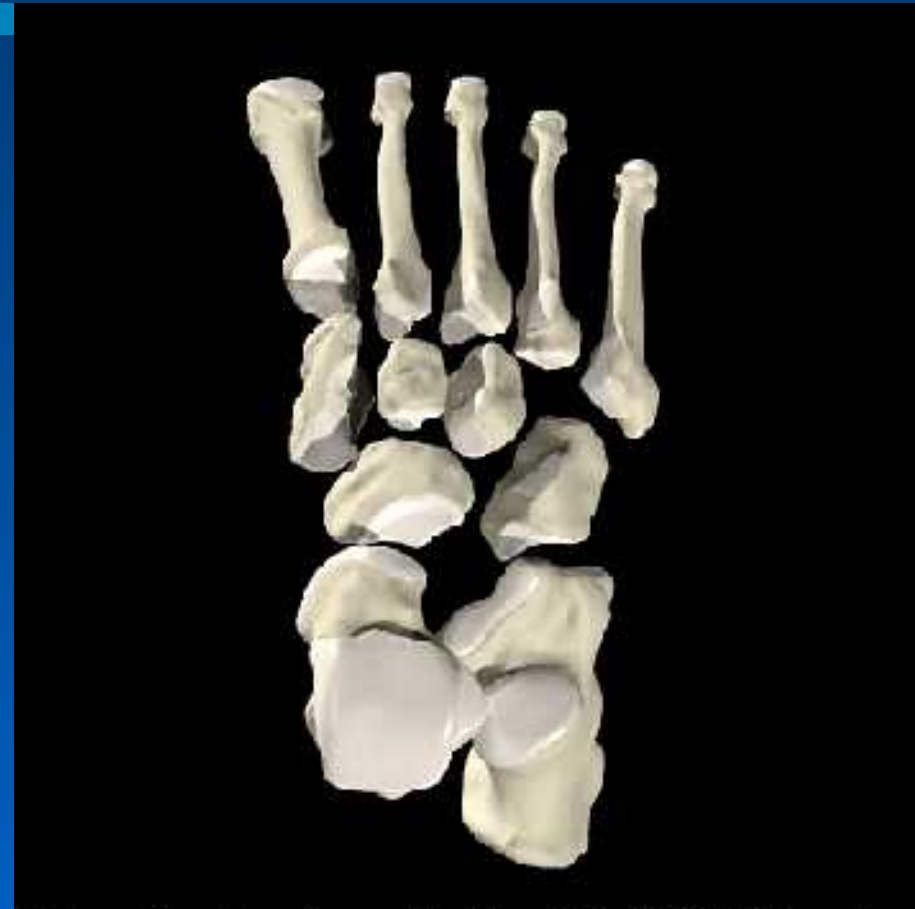Bony Anatomy of Ankle

- Tibia and fibula bound together by the ant. & post. Tibiofibular ligaments and the interosseus membrane which runs between the long bones
- Collectively called the Syndesmotic ligament



Bony Anatomy

- The **Talus** is a wedged shaped bone
 - Wider anteriorly than posteriorly
 - Fits into the mortise formed by the bound tibia and fibula
 - Allows plantar flexion and dorsi-flexion

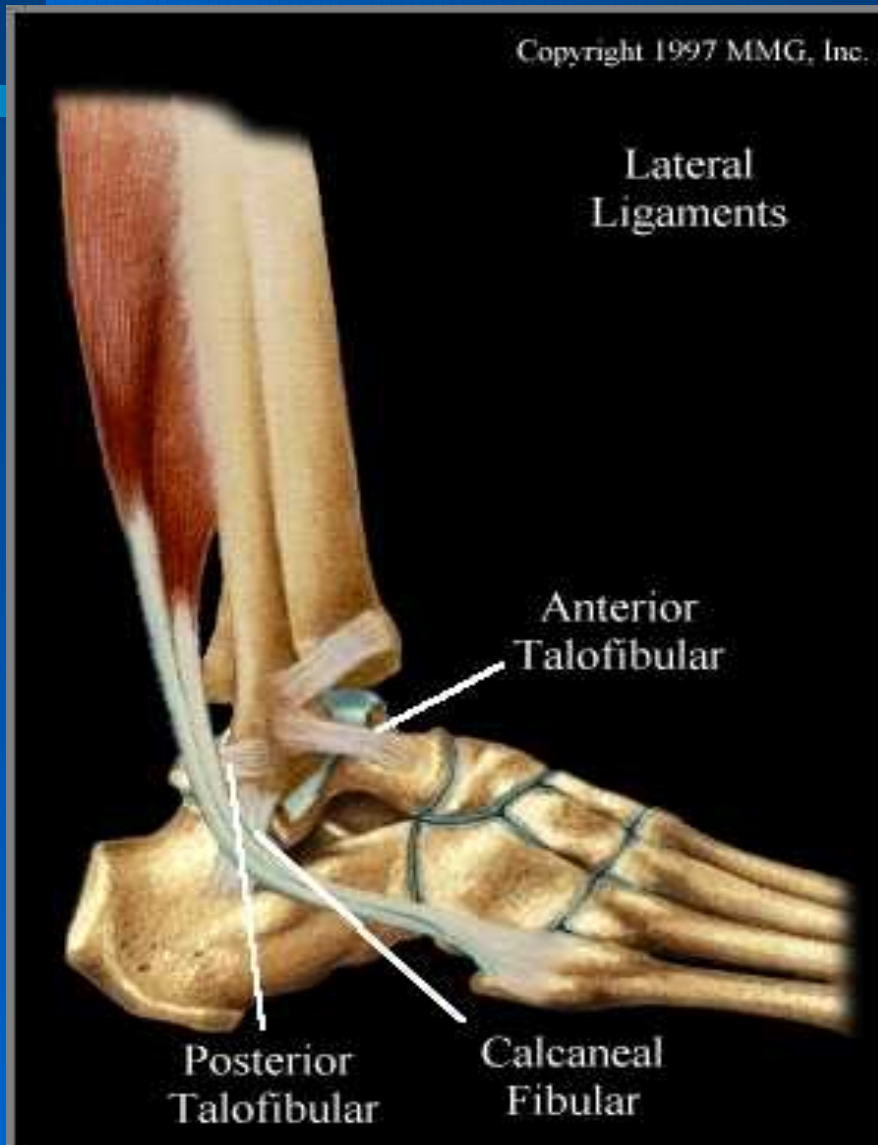

Interactive Foot and Ankle 2 © 2000 Primal Pictures Ltd.

Ligament Injuries

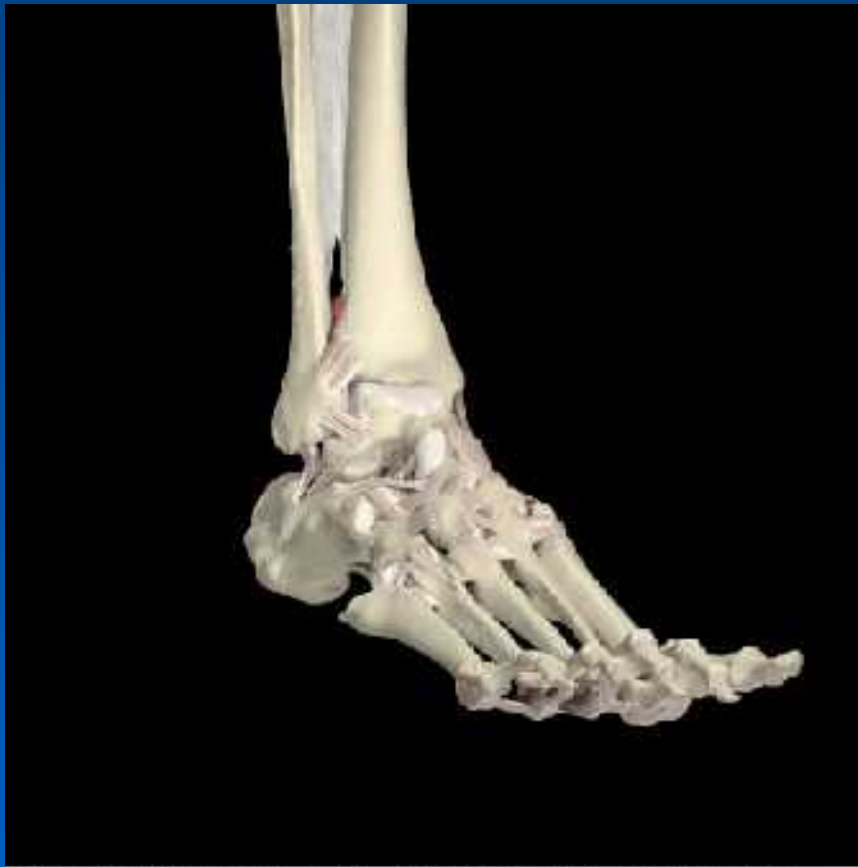- **Lateral ankle sprains (85%)**
 - Plantar flexion and inversion
- **Syndesmotic sprains (10%)**
 - Dorsi-flexion and/or eversion
- **Medial ankle sprains (5%)**
 - Eversion

Lateral Ankle Ligaments



- **Lateral complex**
 - Ant. talofibular
 - calcaneofibular
 - Post. talofibular
- **Syndesmosis**
 - Ant. Inf. tibiofibular
 - Post. Inf. tibiofibular

Syndesmotic Structures

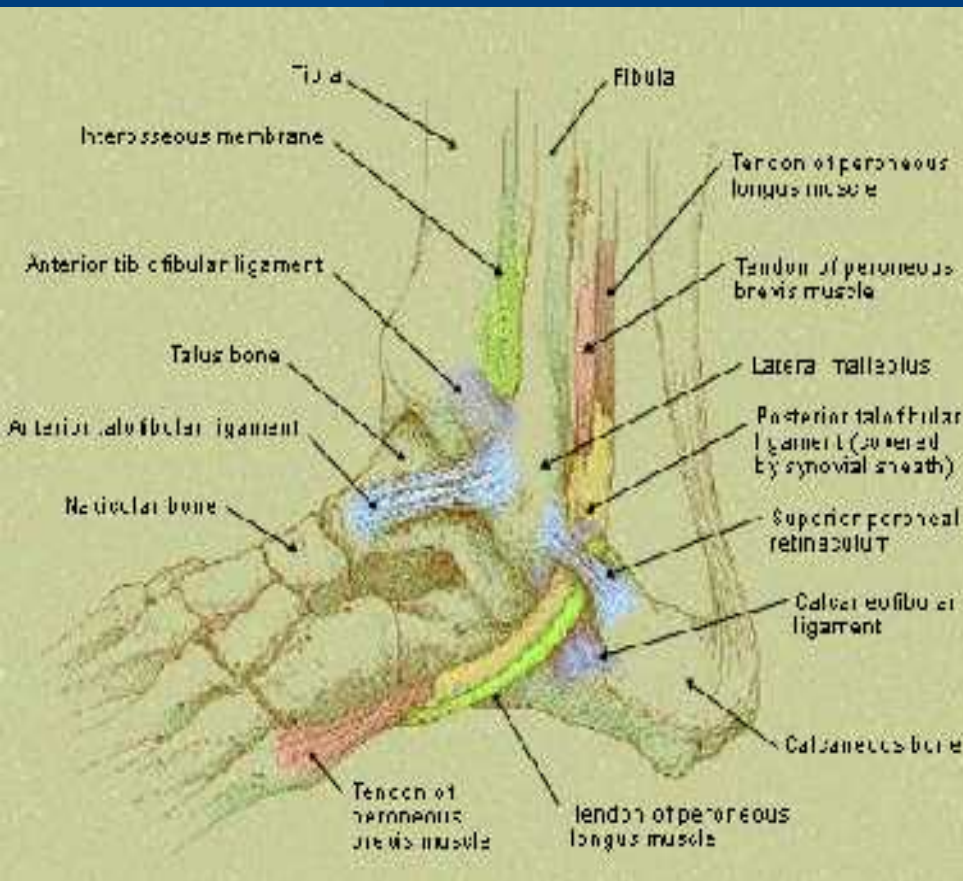


- **Syndesmosis:**
 - Ant. Inf. Tibiofibular ligament
 - Post. Inf. Tibiofibular ligament
 - Transverse tibiofibular ligament
 - Interosseous membrane

Major Functions of Ligaments

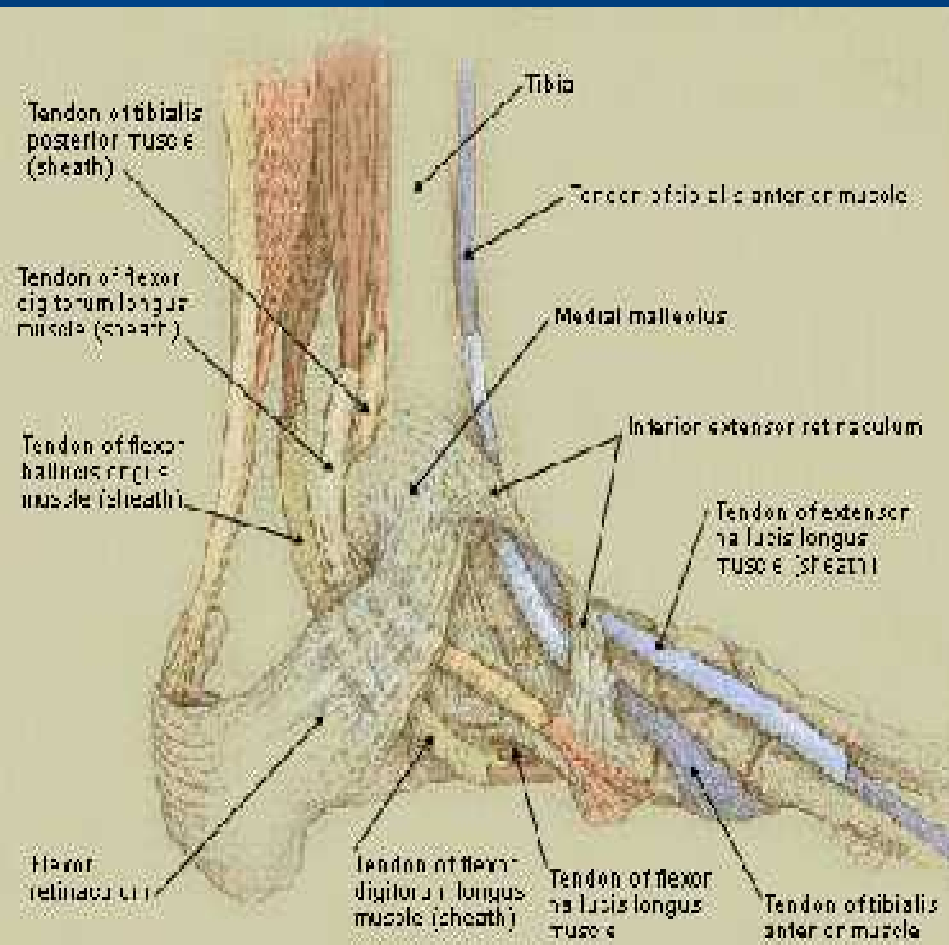
- **Provide proprioceptive information for joint function**
- **Provide static stability to the joint and prevent excessive motion**
- **Act as guides to direct motion**

Tendons of the Lateral Ankle



- **Peroneus brevis**
- **Peroneus longus**
 - Both serve as the major everters of the ankle
 - Also serve as plantar flexors

Ankle Tendons (medial side)



- **Major tendons**

- **Anterior tibialis**
(dorsi-flexor)

- **Achilles tendon**
(plantar flexor)

- **Medial tendons**

- **Posterior tibialis** (inverter and plantar flexor)
- **Flexor digitorum longus**
- **Flexor hallucis longus**

Anatomy Summary

- **Osseous Structures (bare bones)**
 - Tibia, fibula, talus
- **Ligaments (static stabilizers)**
 - Lateral, medial, syndesmotic
- **Muscles/Tendons (dynamic stabilizers)**
 - Plantar & Dorsi-flexors
 - Everters (peroneals)
 - Inverters (post & ant tibialis)

Clinical Exam of the Ankle

- **History is always good!**
 - What happened?
 - Which way did it bend?
 - Could you walk?
 - How much swelling/ecchymosis?
 - When did it happen?
 - What have you done for it?
 - Have you sprained it before?

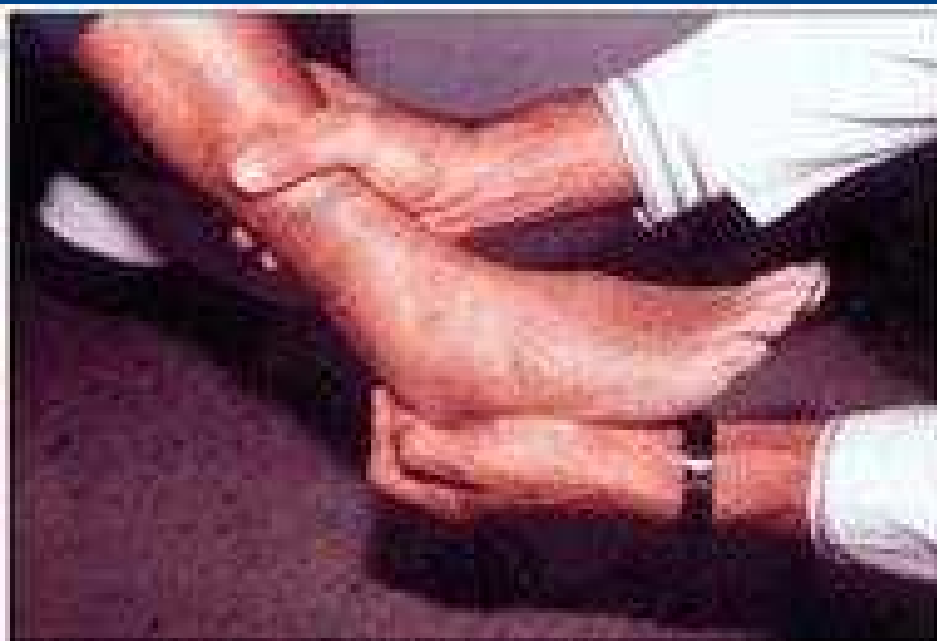Clinical Exam of Ankle

- **Inspection & Palpation:**
 - Most helpful during the acute phase
 - Remember your anatomy!
 - Palpate the structures you know
 - Boney prominences
 - Ligaments
 - Tendon insertions

Clinical Exam of the Ankle

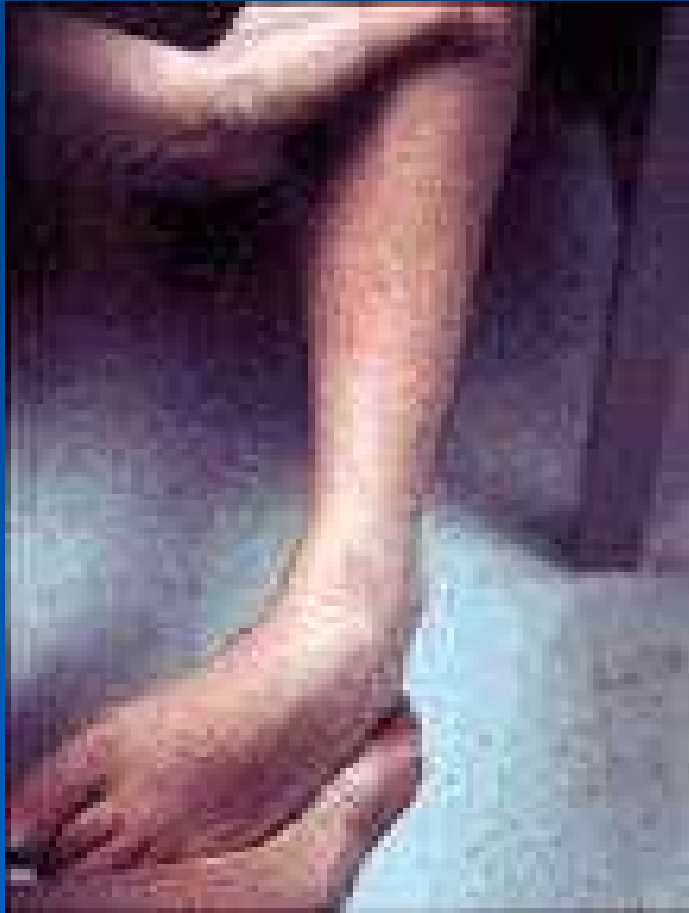- **Check Range of Motion**
 - **Plantar and Dorsi-flexion**
 - **Inversion and Eversion**
- **Neurovascular status**
- **Strength?**
 - **Not helpful in the acute setting**
- **Ligamentous testing**
 - **May be very difficult to do in the acute setting**

The Anterior Drawer



- Tests the integrity of the anterior talofibular ligament

Inversion Stress Test



- Tests the integrity of the calcaneo-fibular ligament

Evaluating for Syndesmotic injury

Figure 3: Courtesy of Todd Hockenbury, MD

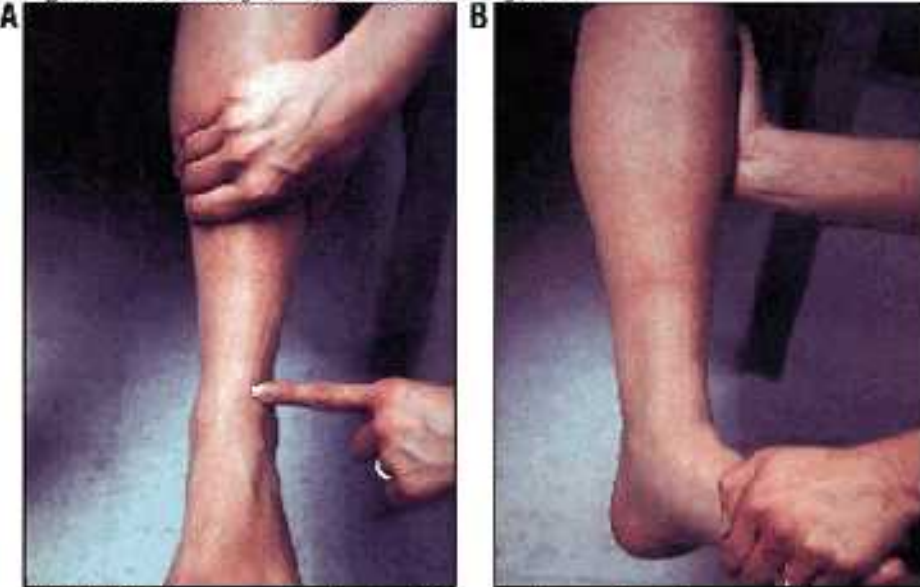


FIGURE 3. Two provocative tests for syndesmotic injury are the squeeze test (A) and the external rotation stress test (B).

To perform the squeeze test (A), the examiner compresses the tibia and fibula above the ankle. Pain at the distal syndesmosis (indicated by finger) confirms distal syndesmotic ligamentous injury.

To perform the external stress test (B), the examiner grasps the medial border of the foot with one hand and supports the lateral tibia and fibula with the other hand. Upon external rotation of the foot, pain at the distal syndesmosis confirms distal syndesmotic ligamentous injury. Antero-posterior and lateral stress radiographs may be taken to reveal diastasis of the distal tibiofibular joint.

- 2 Tests for injury to the syndesmosis
 - The Squeeze test
 - External rotation test

Don't forget the Achilles Tendon

- **The Thompson Test**

- Tests the integrity of the Achilles tendon
- Test patient prone with feet hanging off table
 - squeezing the gastrocnemius muscle should cause plantar flexion of the foot.....
 - If the Achilles tendon is intact!
- It is poor form to miss this diagnosis

To X-ray or not to X-ray?

- **Let's talk Ottawa Ankle Rules**

- **Xrays are indicated to r/o fx if:**

- **Presents within 10 days of injury**
- **Unable to bear weight at time of injury or in office**
- **Tenderness of distal 6cm of malleoli on the post. Aspect.**
- **Tenderness over the base of the 5th met or navicular bone**

Classification of Ankle Sprains

- **Several Classifications Exist based on:**
 - Ligamentous injury and evidence of instability
 - Classification based on functional impairment
 - Number of ligaments involved
- **Combination of the above**

Grade I sprain (usually not seen in the office)

- **Ligament status**
 - partial tear of the ligament
 - mild tenderness and swelling
 - no instability on exam when stressing ligament

- **Functional status**
 - Slight or no functional loss
 - able to bear weight and ambulate with minimal pain

Grade II Ankle Sprain (what we will see a lot!)

- **Ligament Status**

- Incomplete tear of the ligament
- Moderate pain swelling and tenderness
- Mild to mod. ecchymosis
- Mild to moderate instability of the ligament

- **Functional status**

- Some loss of motion and function
- patient has pain with weight-bearing and ambulation

Grade III Ankle Sprain

- **Ligament Status**

- Complete tear and loss of integrity of a ligament.
- Severe swelling (more than 4cm around the fibula)
- Severe ecchymosis
- Significant mechanical instability with ligament stressing

- **Functional Status**

- Significant loss of function and motion
- patient is unable to bear weight or ambulate.

Prognosis inversely related to Grade

– Grade I

- Require an avg. 11.7 days before full resumption of athletic activity

– Grade II

- Require approximately 2-6 weeks

– Grade III

- Avg duration of disability ranges 4.5-26 wks
- Only 25-60% being symptom free 1-4 yrs after injury

Acute Treatment of Ankle Sprains

– PRICEM

– Protection: (orthosis or brace)

– Rest: limit wt. Bearing until non-painful

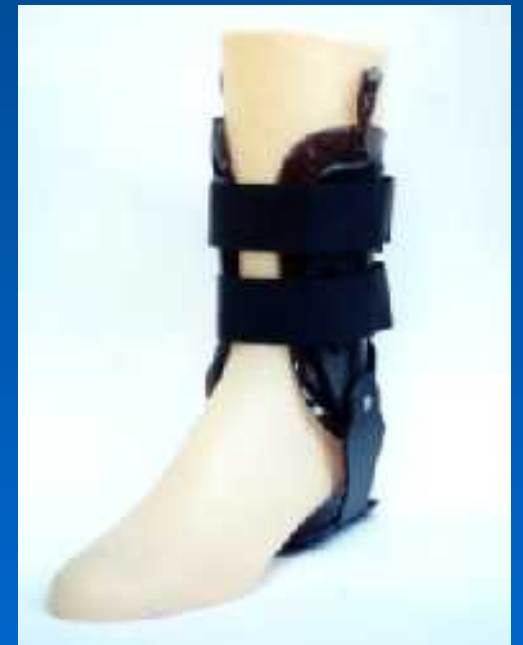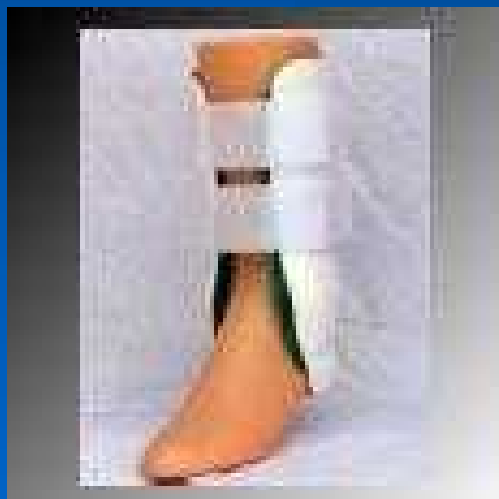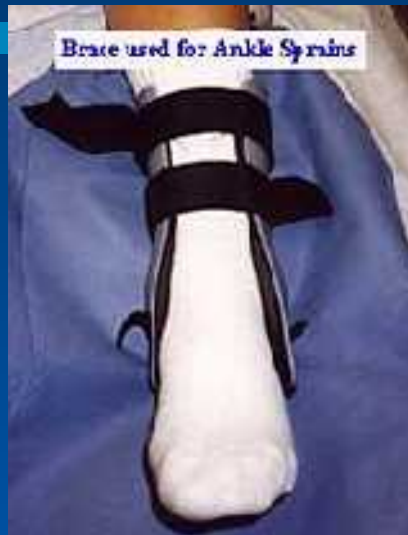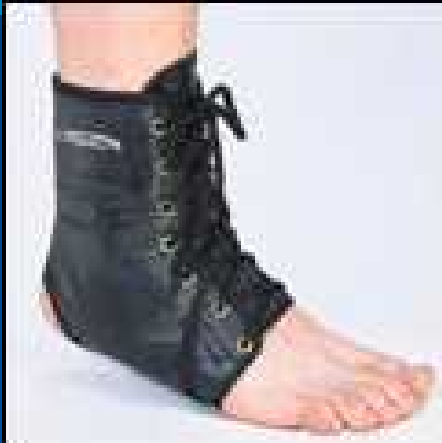– Ice, Compression, and Elevation

- Most important component acutely
- Limiting inflammation and swelling has been shown to speed recovery

– Mobilize

- early range of motion has also been shown to speed recovery

Ankle Braces



What does the Evidence show?

- **What is the best treatment of Grade III sprains?**
 - **Meta-analysis of RCT's from 1966-1998**
 - **outcomes**
 - time lost, residual pain, and giving way
 - **Recommendations for practice**
 - **Manage with aggressive functional tx or surgery followed by functional treatment**

Additional Evidence

- **What's the best intervention to prevent ankle injuries?**
- **Cochrane Review 1997**
 - 5 RCT/quasi-RCT
 - **Concluded:**
 - Found good evidence of a beneficial effect of semi-rigid orthosis or air-cast braces to prevent ankle sprains during high risk sports
 - Individuals with previous injuries showed greatest benefit.

Most Recent Evidence

- **Are Ankle Sprains Preventable**
 - Am J Sports Med 1999
 - Meta-analysis by CDC of 113 studies
 - **Bottom line:**
 - The main risk factor for an ankle sprain is a previous injury.
 - Rehabilitating ankle sprains appears to prevent subsequent sprains

Summary of Ankle Injuries

- Reviewed anatomy and clinical exam
- Ankle injuries are extremely common with high potential for long term sequelae.
- A thorough exam and early aggressive treatment including a rehabilitation program will lead to optimal results.