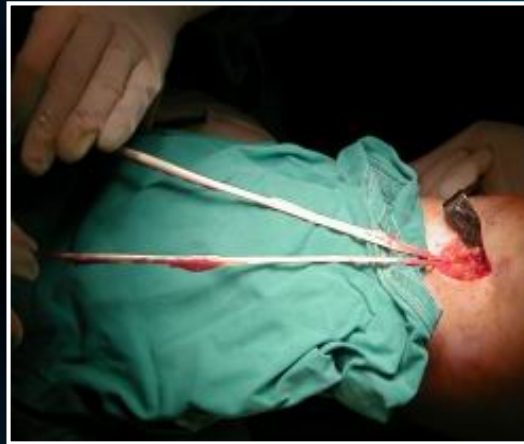

ACL RECONSTRUCTION USING QUADRUPLED HAMSTRING TENDON GRAFT: COMPARISON OF TWO TYPES OF SOFT TISSUE FIXATION

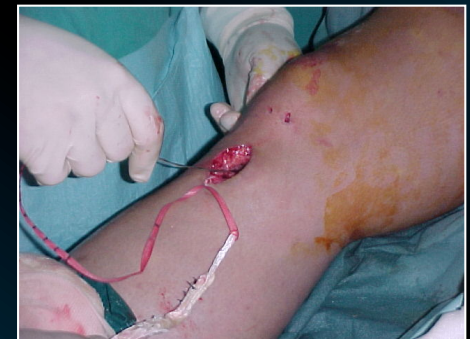

*C.K. YIANNAKOPOULOS, E. ANTONOGIANNAKIS, K. KARLIAFTIS,
V. TZORTZAKIS, G. BABALIS, K. KOTSIPOULOS,
C. KARAMBALIS, P. EFSTATHIOU*

**2nd Orthopaedic Department
401 General Army Hospital
Athens, Greece**

INTRODUCTION

- ✓ Quadrupled hamstring tendon autograft is a very strong ACL reconstruction graft sparing the extension mechanism.
- ✓ The results of this type of reconstruction are comparable to those using BPTB.
- ✓ We are presenting the results of arthroscopic ACL reconstruction using hamstring autograft and compare two types of soft tissue fixation.



PATIENTS- METHODS

Time period: *March 1999- December 2000*

Groups A & B

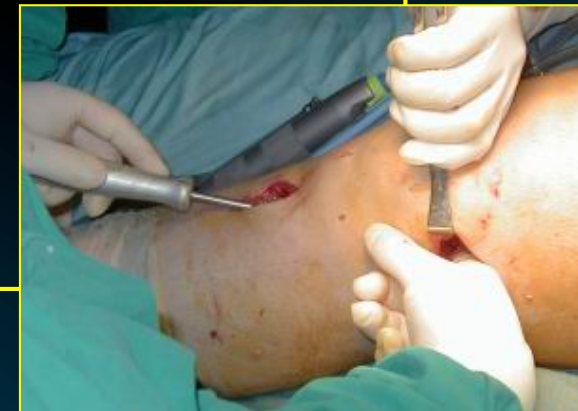Patients: **146**

Reason for reconstruction: *chronic ACL deficiency*

Procedure: *Arthroscopic ACL reconstruction using quadrupled hamstring tendon autograft*

Gender: *male*

Age: *19-37 years*



PATIENTS- METHODS


Group A

Patients: 87

Type of graft: *Quadrupled semitendinosus-gracilis autograft*

Type of fixation: *special soft tissue fixation device (Mark II, Surgicraft,UK)*

femur : over the top & bollard fixation
tibia : tunnel & bollard fixation



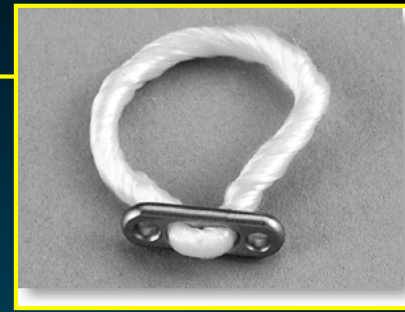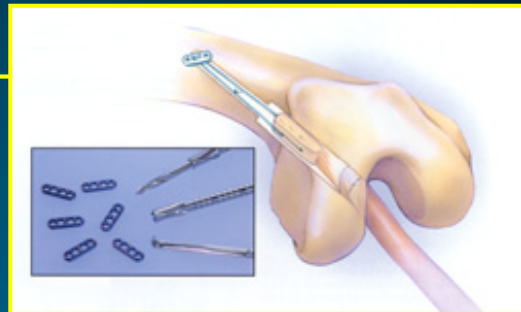
PATIENTS- METHODS

Group B

Patients: *59*

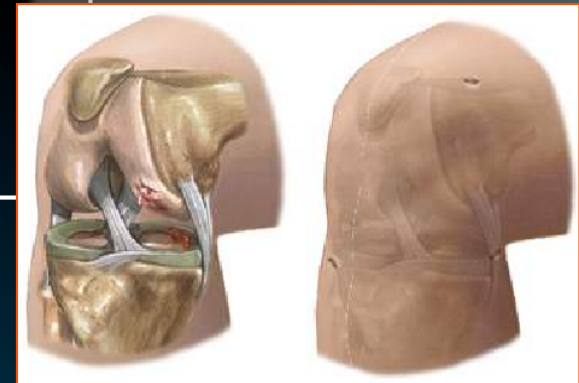
Type of graft: *Quadrupled semitendinosus-gracilis autograft*

Type of fixation: *special fixation system*
(Endobutton, Smith & Nephew)
femur : tunnel & endobutton
tibia : tunnel & interference screw

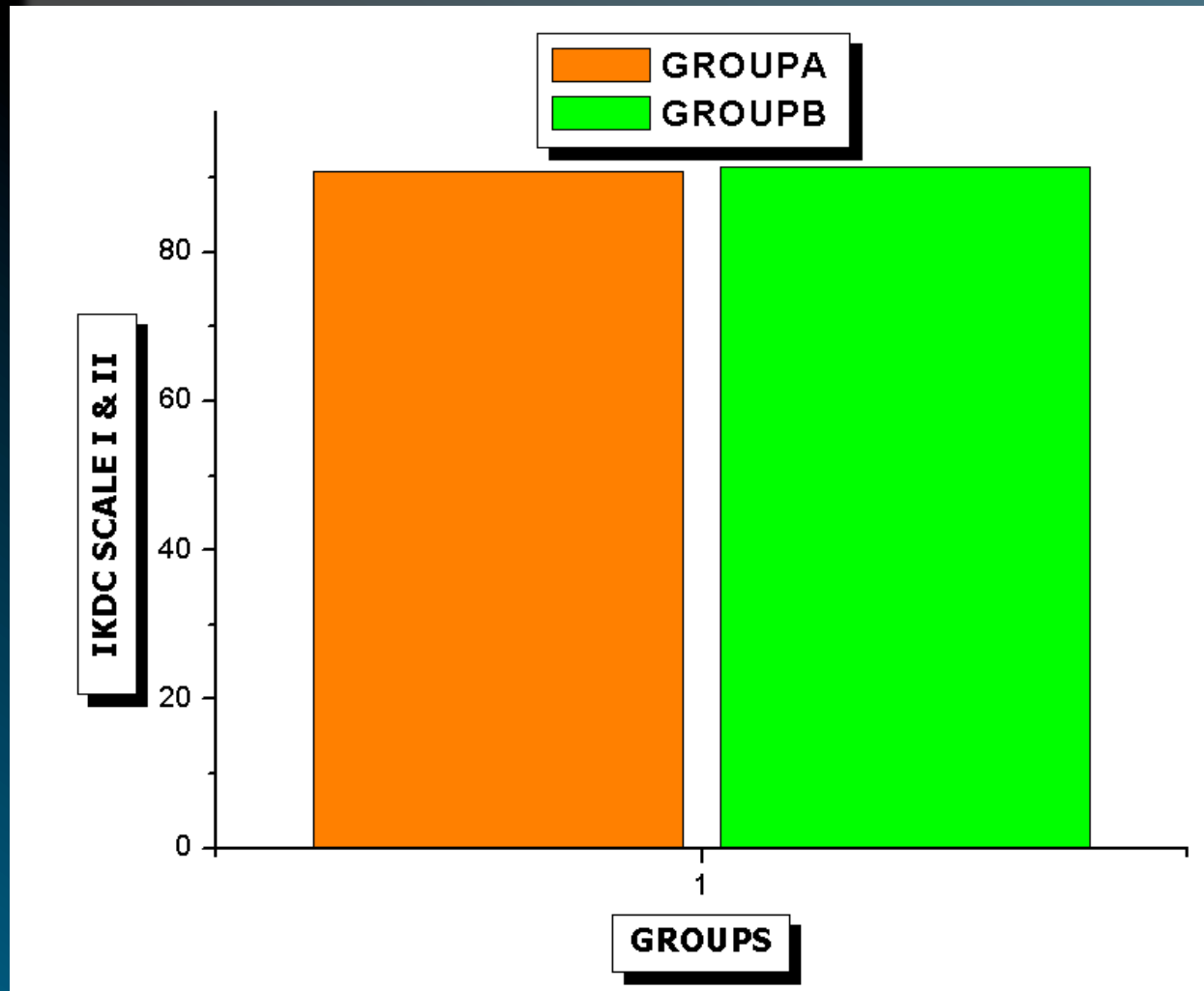


EVALUATION

- IKDC
- Lysholm-Tegner scale
- Total subjective evaluation
- Hop test - Hop Index -Vertical Jump Test
- ROM
- Symptoms
- I sokinetic evaluation
- Pivot shift
- Lachman test



RESULTS



There was no significant difference between the two fixation methods

CONCLUSION

Both techniques proved to be safe, effective and reproducible in restoring knee function with minimal donor site morbidity the procedure during which the autograft was passed and fixed in the femur at the “over the top” position using Mark II fixation system seems to be more time saving avoiding many of the problems of the through the tunnel positioning



REFERENCES

1. Feller JA, Webster KE, Gavin B. Early post-operative morbidity following anterior cruciate ligament reconstruction: patellar tendon versus hamstring graft. *Knee Surg Sports Traumatol Arthrosc* 2001 Sep;9(5):260-6
2. Jarvela T, Kannus P, Jarvinen M. Anterior knee pain 7 years after an anterior cruciate ligament reconstruction with a bone-patellar tendon-bone autograft. *Scand J Med Sci Sports* 2000 ;10 (4):221-7
3. Kartus J, Movin T, Karlsson J. Donor-site morbidity and anterior knee problems after anterior cruciate ligament reconstruction using autografts. *Arthroscopy* 2001 Nov-Dec;17(9):971-80
4. Kartus J, Ejerhed L, Sernert N, et al. Comparison of traditional and subcutaneous patellar tendon harvest. A prospective study of donor site-related problems after anterior cruciate ligament reconstruction using different graft harvesting techniques. *Am J Sports Med* 2000 May-Jun;28(3):328-35
5. Kartus J, Stener S, Lindahl S, Engstrom B, Eriksson BI, Karlsson J. Factors affecting donor-site morbidity after anterior cruciate ligament reconstruction using bone-patellar tendon-bone autografts. *Knee Surg Sports Traumatol Arthrosc* 1997;5(4):222-8
6. Rubinstein RA Jr, Shelbourne KD, VanMeter CD, McCarroll JC, Rettig AC. Isolated autogenous bone-patellar tendon-bone graft site morbidity. *Am J Sports Med* 1994 May-Jun;22(3):324-7
7. Suddemi SR, Frogameni AD, Fenton PJ, Hartman J, Hartman W. Comparison of perioperative morbidity of anterior cruciate ligament autografts versus allografts. *Arthroscopy* 1993;9(5): 519-24
8. Tsuda E, Okamura Y, Ishibashi Y, Otsuka H, Toh S. Techniques for reducing anterior knee symptoms after anterior cruciate ligament reconstruction using a bone-patellar tendon-bone autograft. *Am J Sports Med* 2001; 29(4):450-6
9. Yasuda K, Tsujino J, Ohkoshi Y, Tanabe Y, Kaneda K. Graft site morbidity with autogenous semitendinosus and gracilis tendons. *Am J Sports Med* 1995 Nov-Dec;23(6):706-14

