

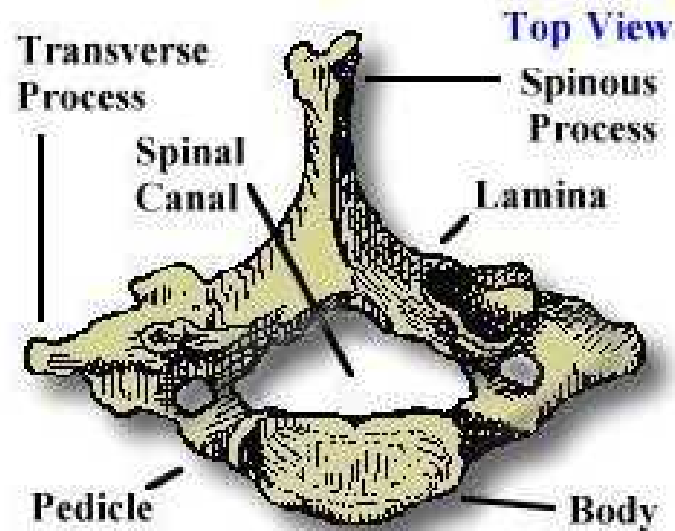
Cervical Spine



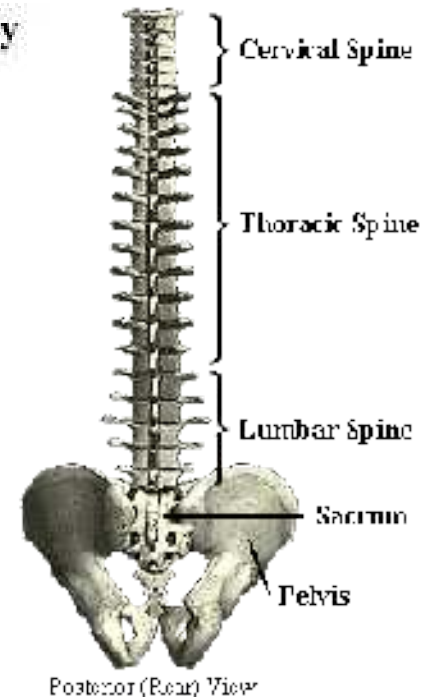
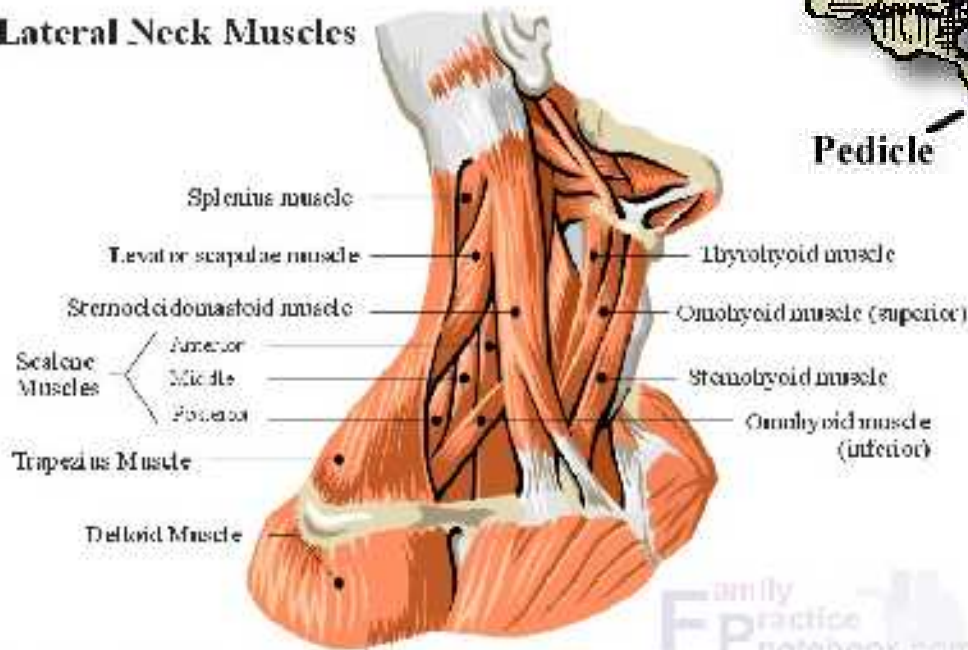
"Where does it hurt?"

Cervical Spine

- C1 - C7

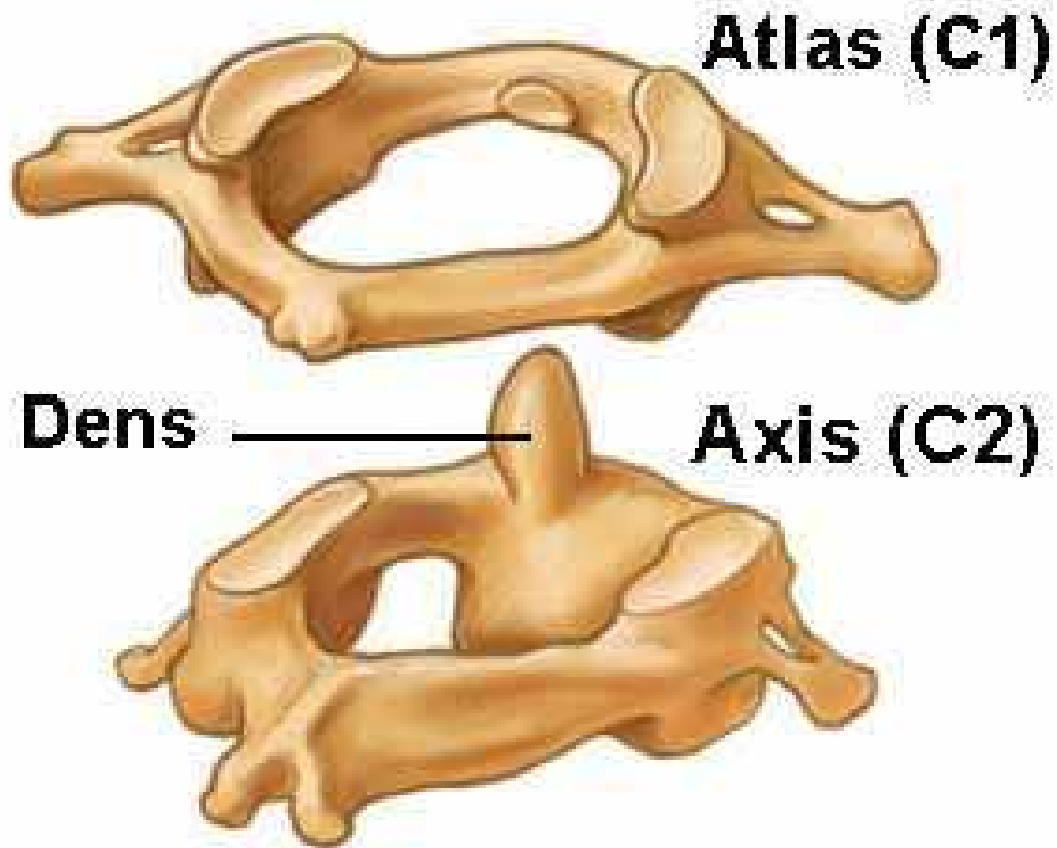


Lateral Neck Muscles



Adapted from Corel Draw 9.0

Atlas and Axis

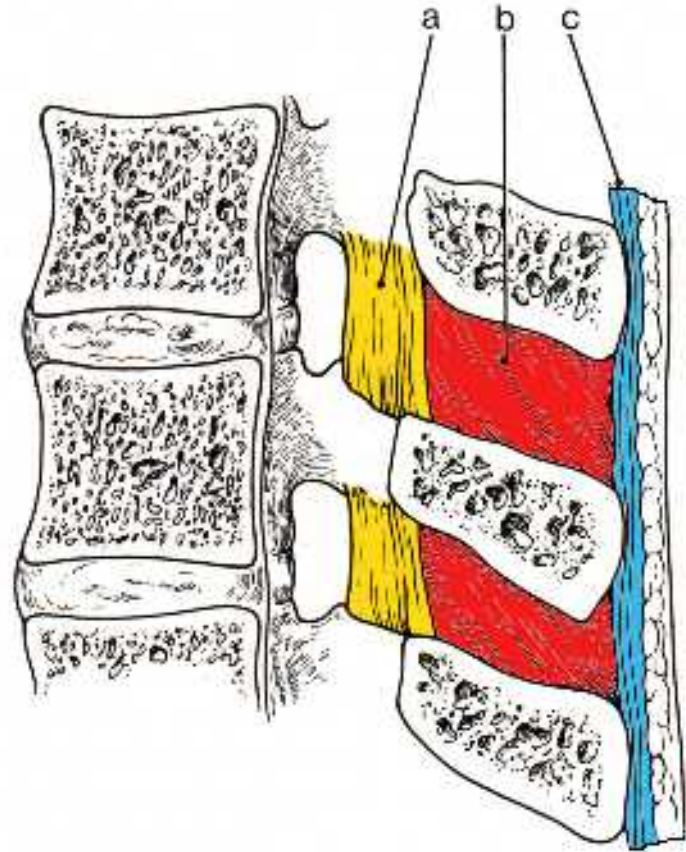


Ligamentous Anatomy

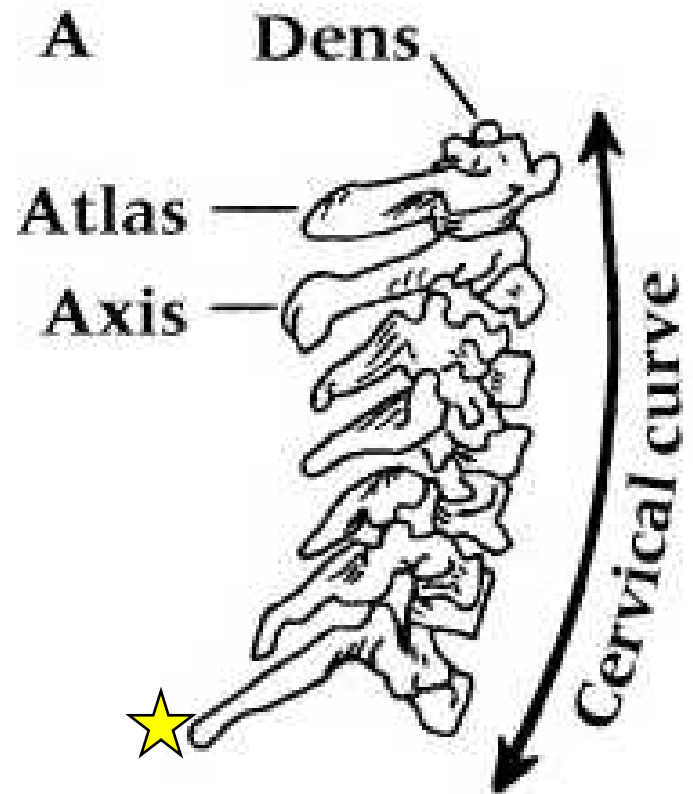
- **Anterior longitudinal ligament**
 - Reinforces anterior discs, limits extension
- **Posterior longitudinal ligament**
 - Reinforces posterior discs, limits flexion
- **Ligamentum nuchae = supraspinous ligament**
 - Thicker than in thoracic/lumbar regions
 - Limits flexion
- **Interspinous/intertransverse ligaments**
 - Limit flexion and rotation/limits lateral flexion
- **Ligamentum flavum**
 - Attach lamina of one vertebrae to another, reinforces articular facets
 - Limits flexion and rotation

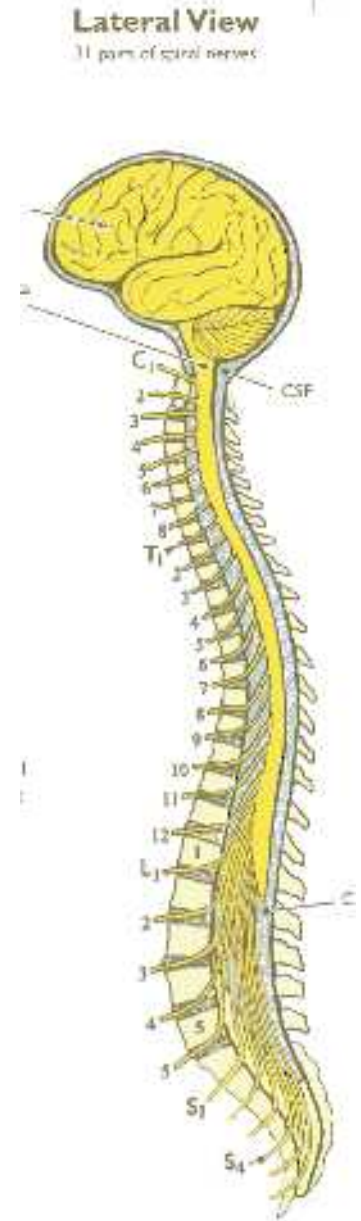
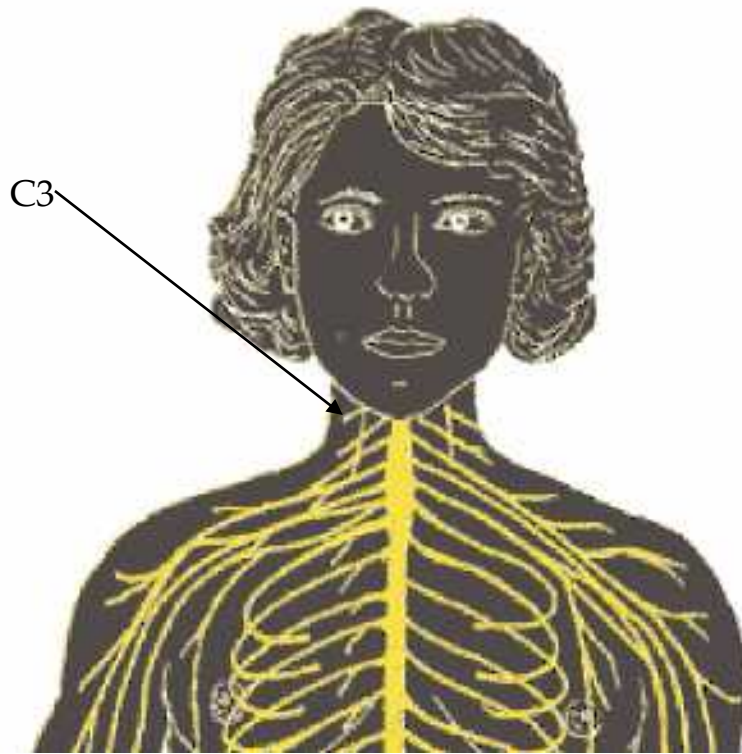
Ligamentous Anatomy

- a = ligamentum flavum
- b = interspinous ligaments
- c = supraspinous ligament



- Palpable C7
- Anterior Curvature
 - Shock absorption
- Ligaments
 - Ligamentum Nuchae
 - “Whiplash”
- Vertebral Arteries





- Spinal Nerves
 - C1-T1
 - Cervical Plexus
 - C1-C4
 - C4 -Phrenic Nerve - Breathing
 - Brachial Plexus
 - C5-T1

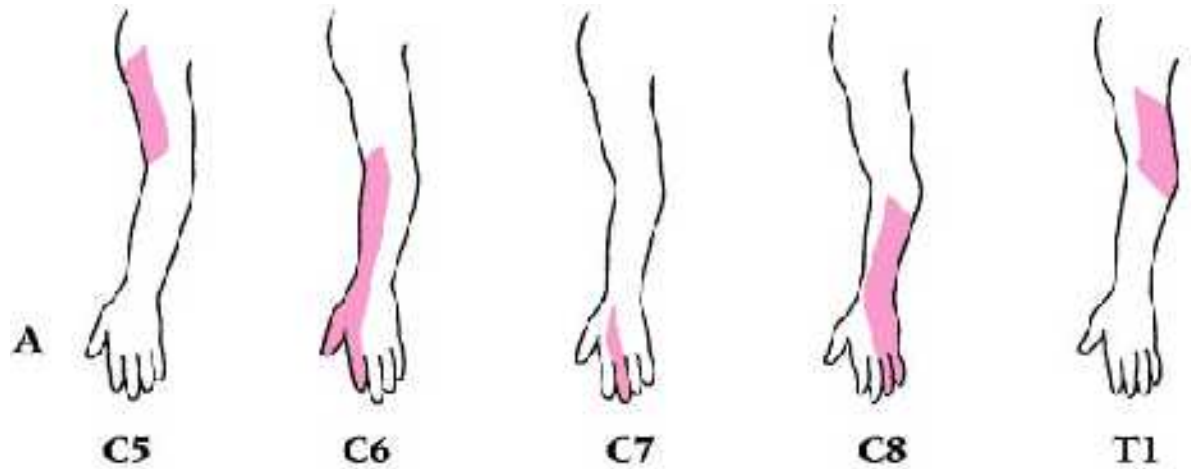
Dermatomes

C1 – top of head

C2 – Temporal

C3 – Side of
jaw/neck

C4 – top of
shoulders



Myotomes

C1-2 – Neck Flexion

C3 – Lateral Neck Flexion

C4 – Shoulder Elevation

C5 – Abduction

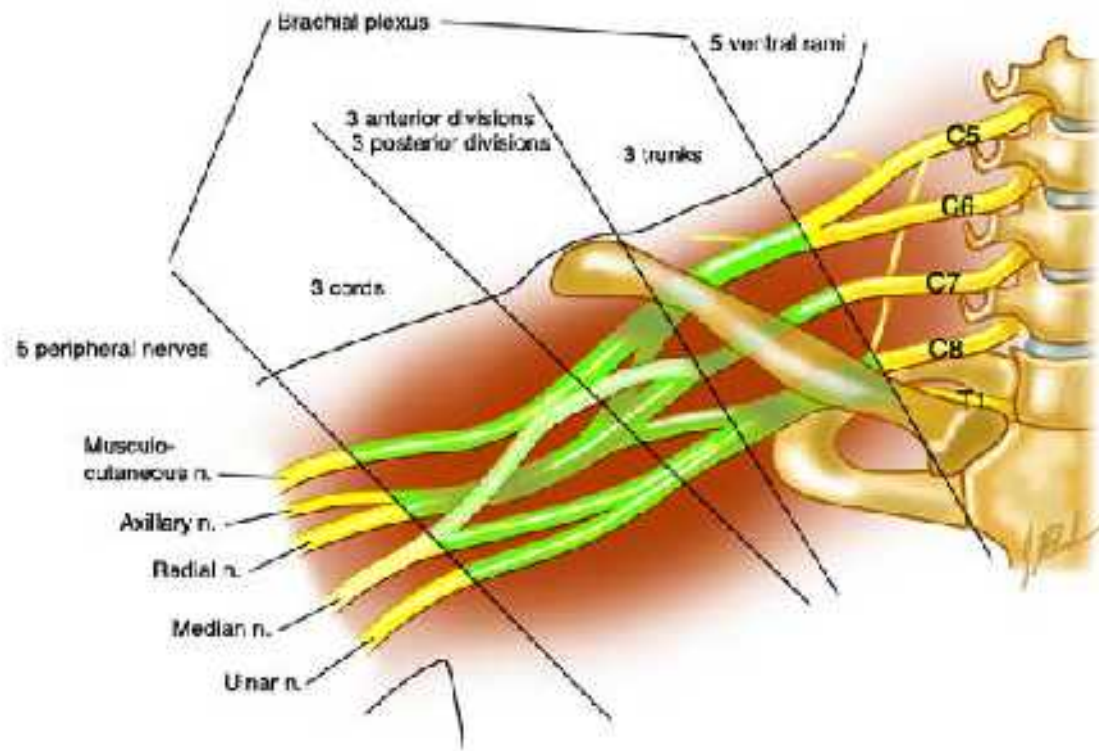
C6 – Elbow Flexion/Wrist Extension

C7 – Elbow Extension/Wrist Flexion

C8 – Finger Flexion

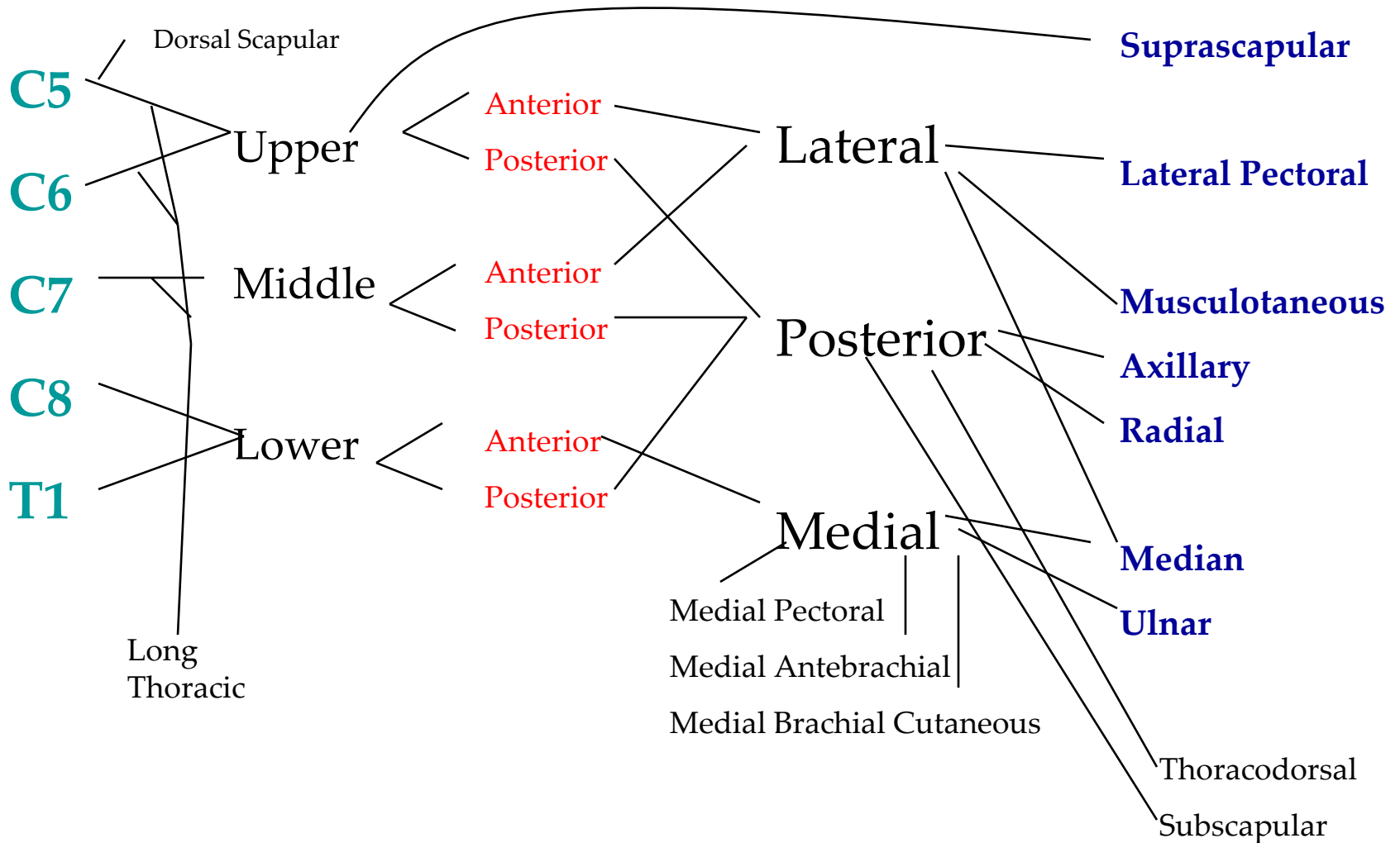
T1 – Finger Abduction

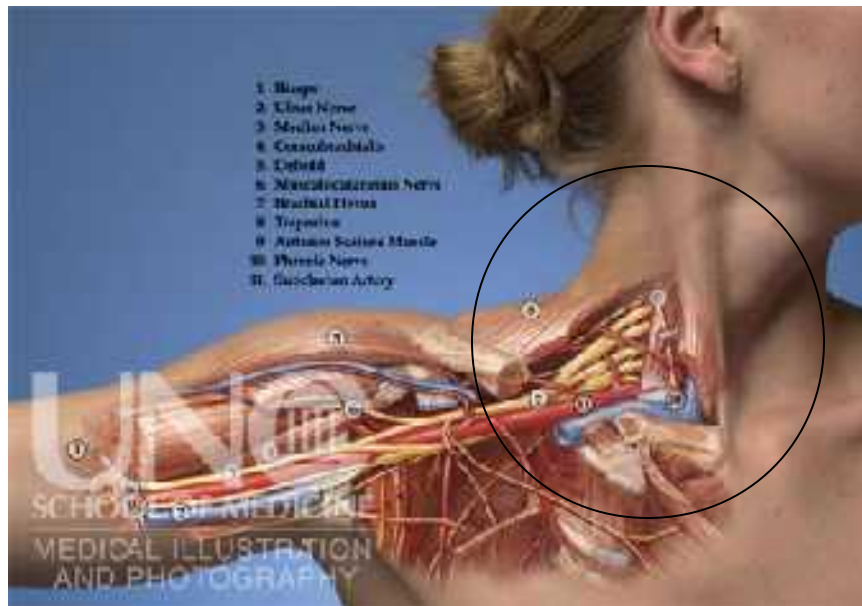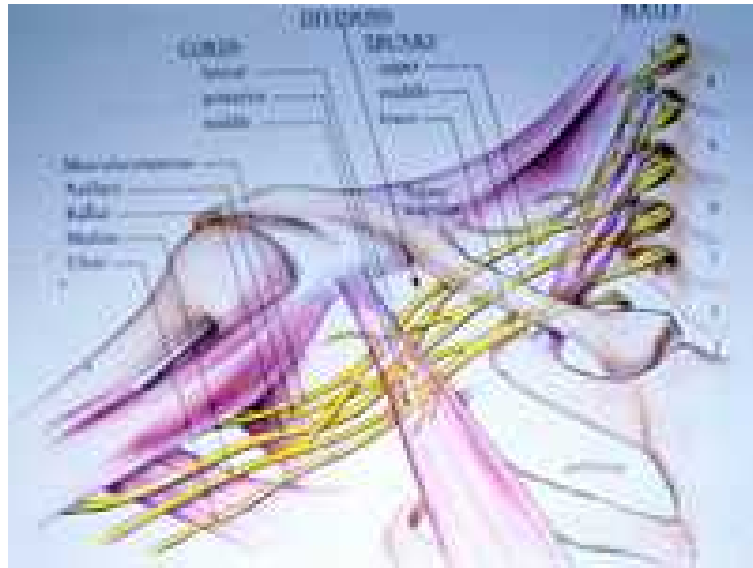
Brachial Plexus



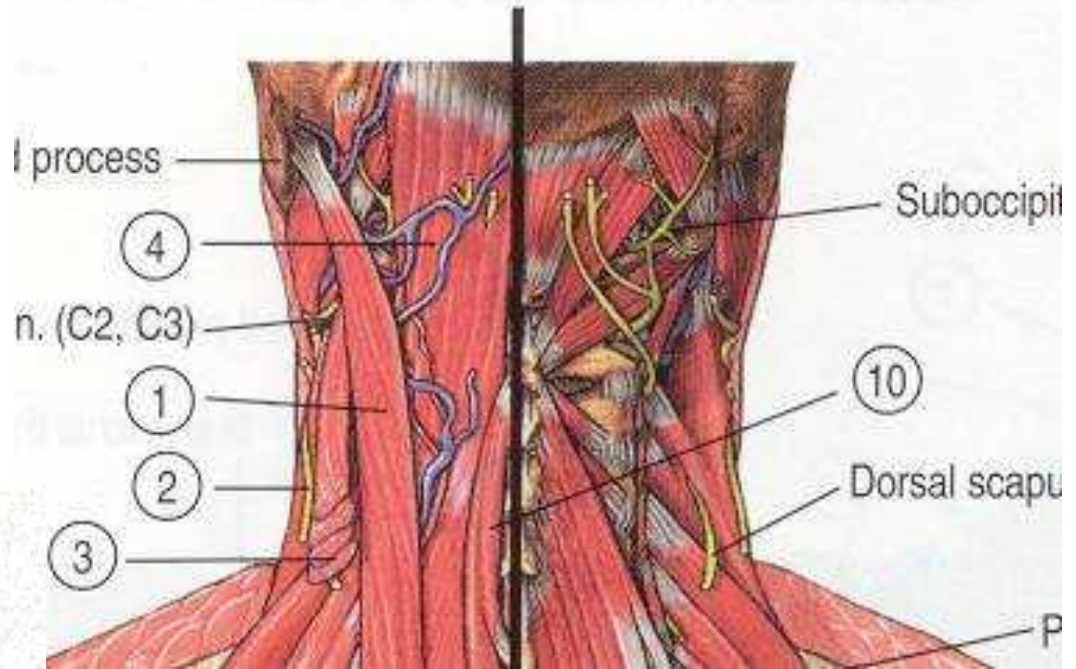
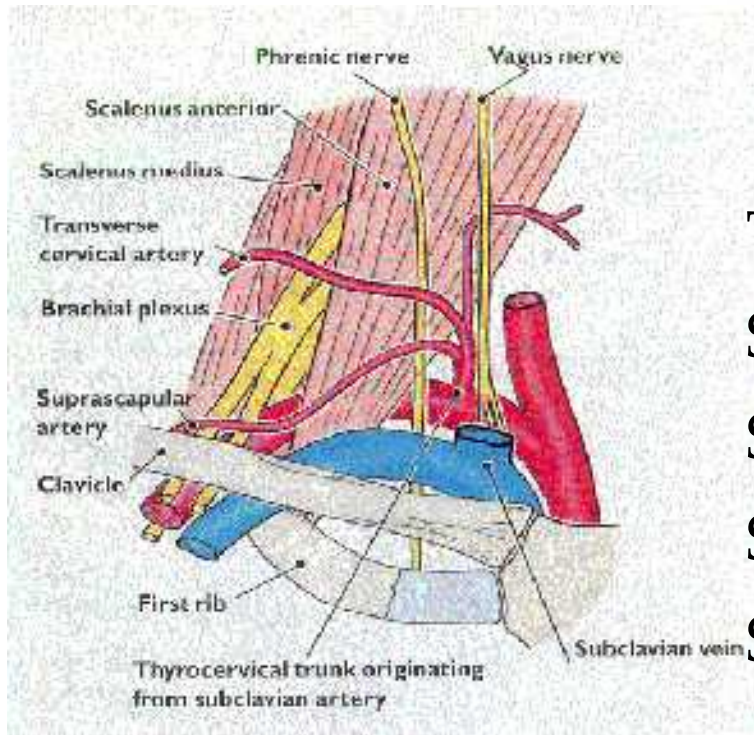
Brachial Plexus

ROOTS TRUNKS DIVISIONS CORDS BRANCHES





- Muscles



Trapezius

Sternocleidomastoid

Scalenes

Splenius

Semispinalis, Spinalis, Longissimus


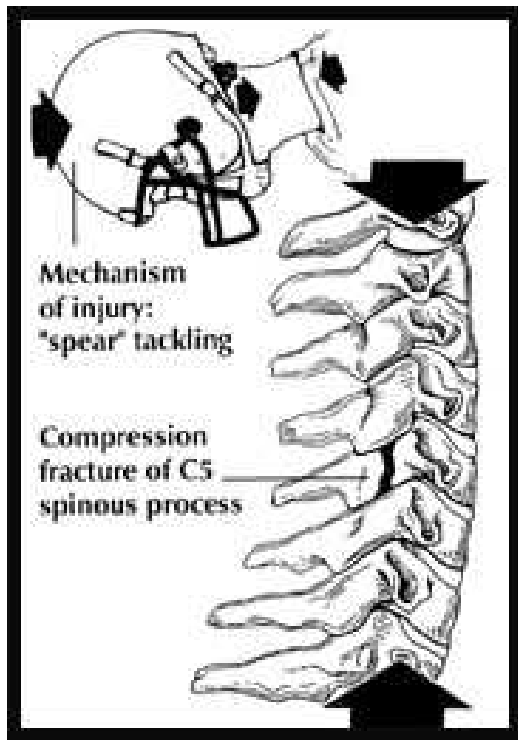
Cervical Injuries

- Fairly uncommon in athletics(6-7%) - but greater than 90% of all fatalities are cervical related.
- Cervical injuries are primarily technique related:
 - **Spearing**
 - Tackling or falling head first.
- Must have an emergency plan:
 - All personnel know roles and equipment use.
 - All unconscious athletes - suspect head/neck
 - Always suspect the worse until proven otherwise

Cervical Injuries

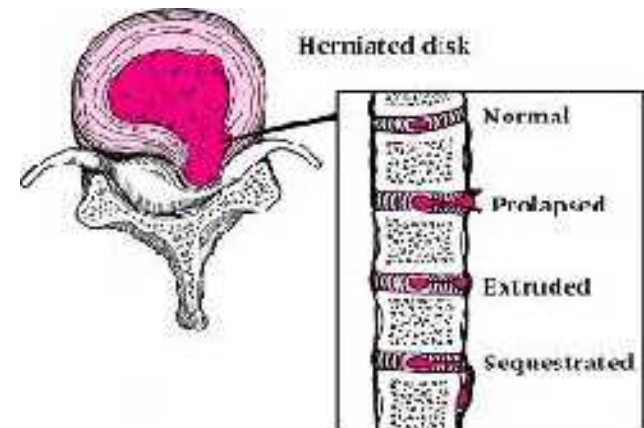
- Common MOIs
 - Axial Loading
 - Flexion Force
 - Hyperextension Force
 - Flexion-Rotation Force
 - Hyperextension-Rotation
 - Lateral Flexion

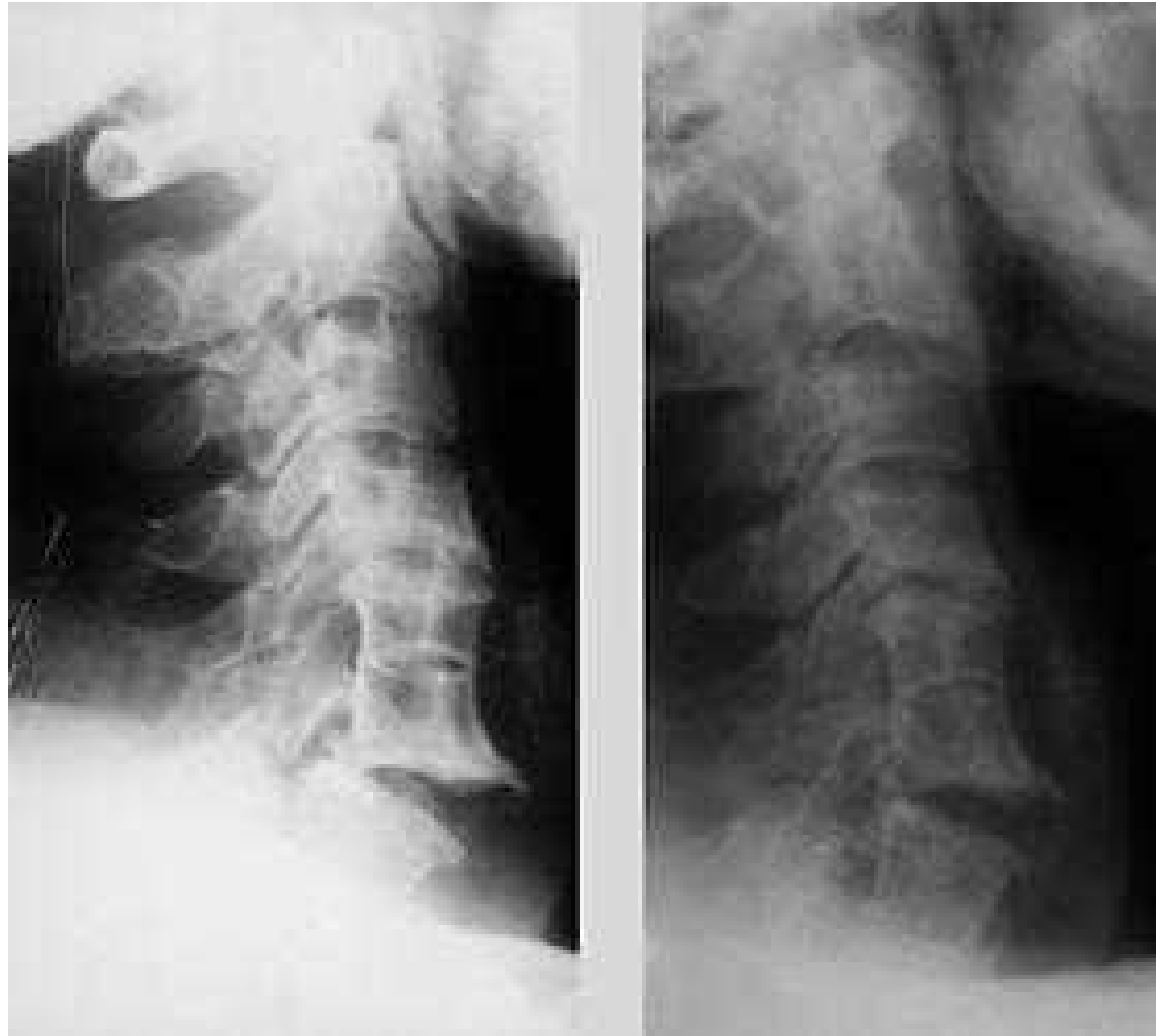


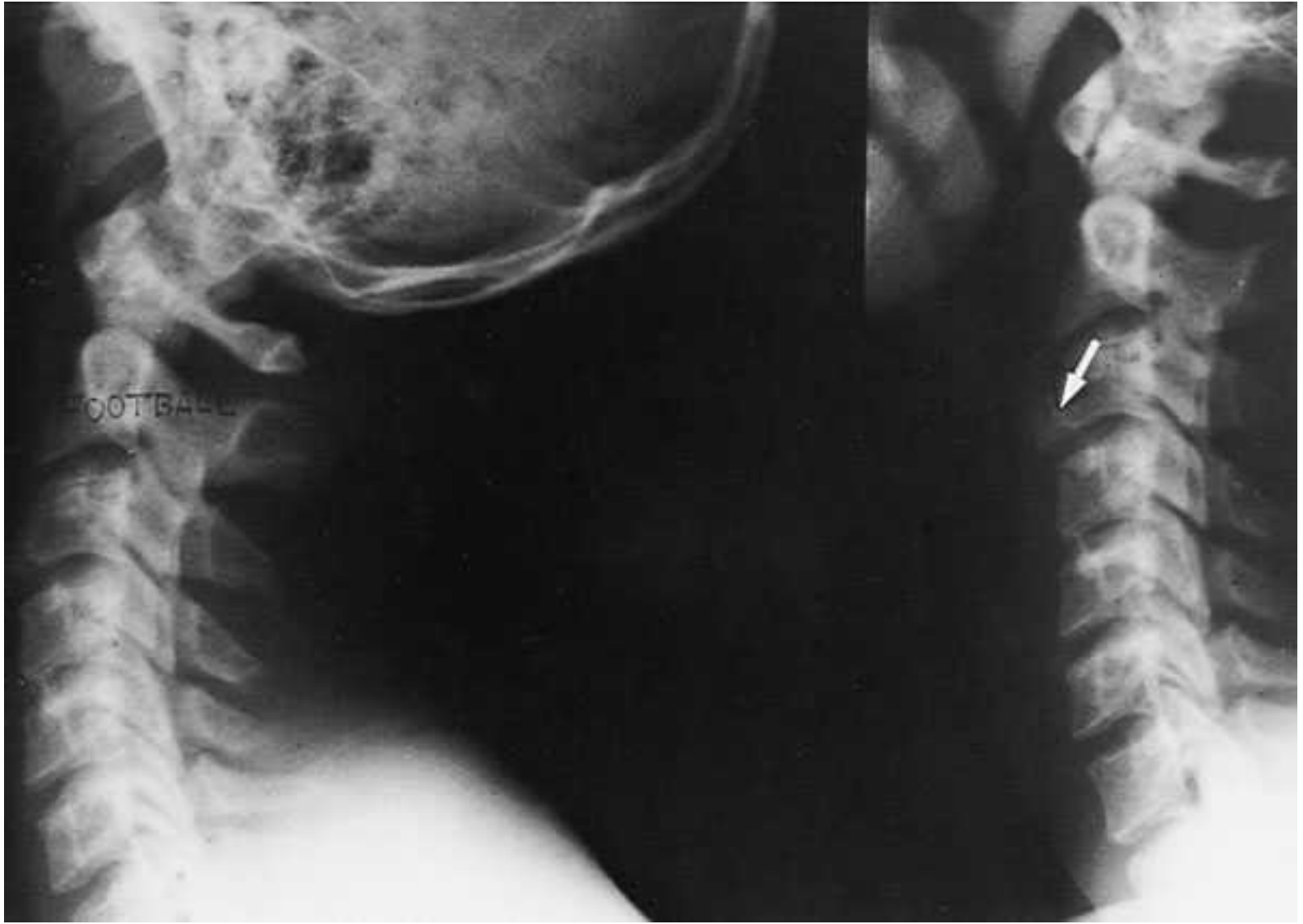

C-Spine Injuries

- Cervical Fracture or Dislocation
 - Weakness or Paralysis
- Cervical Nerve Root Injury
 - Herniated Disc
 - Laceration
 - Cord Shock (Central Cord Syndrome)
 - Hemorrhage
 - Contusion
 - Cervical Stenosis







C-Spine/Neck Injuries

- Cervical Strain
 - Active motion most painful
- Cervical Sprain (Whiplash)
 - Passive and active motion painful
- Torticollis (WryNeck)
 - Muscle spasm and facet irritation
- Brachial Plexus Stretch or Compression
- Contusions to Throat

Evaluation Techniques

- HOPS
 - History, Observation, Palpation, Special Tests
- Your first priority!
 - Establish the integrity of the spinal cord and nerve roots
 - History and several specific tests provide information

History

History

- Location of pain
- Onset of pain
- Mechanism of injury (etiology)
- Consistency of pain
- Prior history of cervical spine injury

Location of Pain

- Localized pain
 - Typically indicative of muscular strain, ligamentous sprain, facet joint injury, fracture and/or subluxation or dislocation
- Radiating pain
 - Heightened risk of likely spinal cord, cervical nerve root and/or brachial plexus injury

Onset of Pain/Mechanism of Injury

- Acute onset
 - Generally associated with one specific mechanism of injury/event
- Chronic or insidious (unknown) onset
 - Generally related to overuse injuries (accumulative microtrauma) and/or postural abnormalities and deficiencies

Consistency of Pain

- Pain from inflammation (strain, sprain, contusion) generally persists despite changes in cervical spine position
- Pain of mechanical nature (nerve root compression) varies depending upon cervical spine positioning and can be minimized or eliminated

Prior History of Cervical Spine Injury

- Must evaluate for residual symptoms associated with previous injury
- Must appreciate structural changes (scar tissue, etc.) which may predispose individual to current injury and symptoms

Inspection

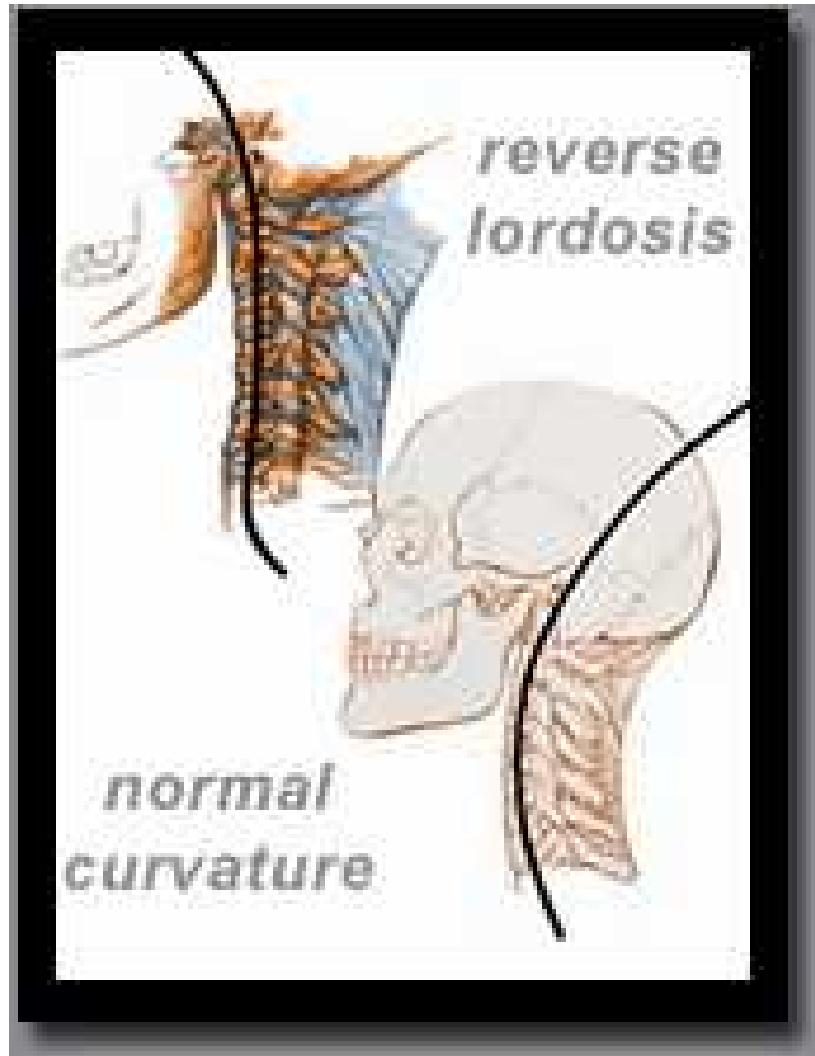
Inspection

- Cervical spine curvature
- Position of head relative to shoulders
- Soft tissue symmetry
- Level of shoulders

Cervical Spine Curvature

- Normal cervical spine has lordotic curve
- Increased lordotic curve (forward head) indicative of poor posture and muscular weakness or imbalance
- Lessened lordotic curve indicative of muscular spasm/guarding and/or nerve root impingement

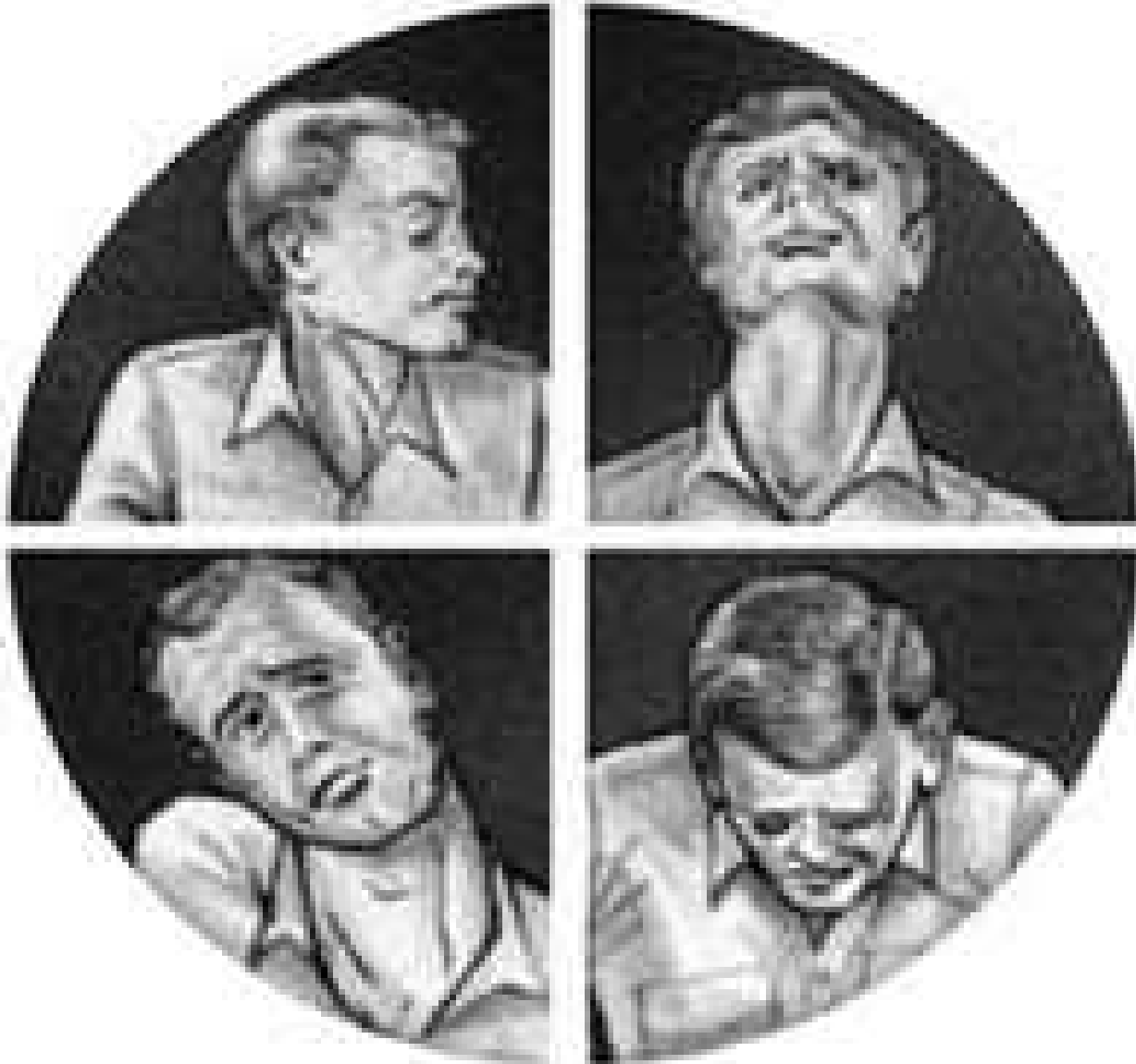Lordotic Curve



Position of Head Relative to Shoulders

- Head should be seated symmetrically on cervical spine
- Lateral flexion from unilateral spasm of muscles – strain and/or spasm (guarding)
- Rotation from unilateral spasm of sternomastoid muscle – strain and/or spasm (guarding) or torticollis

Torticollis



Soft Tissue Symmetry

- Observe for bilaterally comparable muscle mass, tone and contour
 - Dominant extremity may be hypertrophied vs. non-dominant extremity
 - Excessive tone indicative of possible strain/spasm
 - Atrophy indicative of neurological injury

Level of Shoulders

- Inspect height of:
 - Acromioclavicular (AC) joints
 - Deltoids
 - Clavicles
- Dominant extremity often appears depressed relative to non-dominant extremity

Palpation

Anterior Palpation

- Hyoid bone
 - At level of C3 vertebrae, note movement with swallowing
- Thyroid cartilage
 - At level of C4/C5 vertebrae, also moves with swallowing, protects larynx
 - Aka – “Adam’s apple”
- Cricoid cartilage
 - At level of C6/C7 vertebrae, point where esophagus and trachea deviate, rings of cartilage

Anterior Palpation

- Sternomastoid
 - Sternum (near SC joint) to mastoid process
- Scalenes
 - Posterior/lateral to sternomastoid muscles
 - Difficult to differentiate, palpate collectively
- Carotid artery
 - Primary pulse point
- Lymph nodes
 - Only discernable if enlarged due to illness

Posterior and Lateral Palpation

- Occiput
 - Posterior aspect of skull, many ms. attachments
- Transverse processes
 - Can only palpate C1 transverse processes approx. one finger below mastoid processes
- Spinous processes
 - Flex cervical spine, C7 and T1 are prominent
 - Can palpate C5 and C6, maybe C3 and C4
- Trapezius
 - Upper fibers from occiput and cervical spinous processes to distal clavicle

Special Tests

Special Tests

- Range of motion testing
 - Active
 - Passive
 - Resisted
- Ligamentous/capsular tests
- Neurological tests
 - Brachial plexus evaluation
 - Reflex tests
 - Upper motor neuron lesions

Active Range of Motion

- Best done in sitting or standing
- Flexion – touch chin to chest
- Extension – look straight above head
- Lateral flexion – approximately 45 degrees
- Rotation – nose over tip of shoulder

Passive Range of Motion

- Best done laying supine
- Flexion – firm end feel
- Extension – hard end feel (occiput on cervical spinous processes)
- Lateral flexion – firm end feel (stabilize opposite shoulder)
- Rotation – firm end feel

Resisted Range of Motion

- Easiest to perform all in seated position – stabilize proximally to avoid substitution
- Flexion – resistance to forehead
- Extension – resistance to occiput
- Lateral flexion – resistance to temporal and parietal regions
- Rotation – resistance to temporal region or side of face

Ligamentous/Capsular Testing

- No specific named tests for cervical spine
- End feels associated with passive ranges of motion essentially become end points for joint capsule and ligamentous stress tests

Neurological/Vascular Tests

- Brachial plexus evaluation
 - Dermatomes = sensory map
 - Myotomes = motor function
 - Reflex tests
 - Brachial plexus traction test
 - Cervical distraction/compression tests
 - Spurling test
- Upper motor neuron lesions
 - Babinski test
 - Oppenheim test
 - Loss of bowel and/or bladder control
- Vertebral artery test

Brachial Plexus - Dermatomes

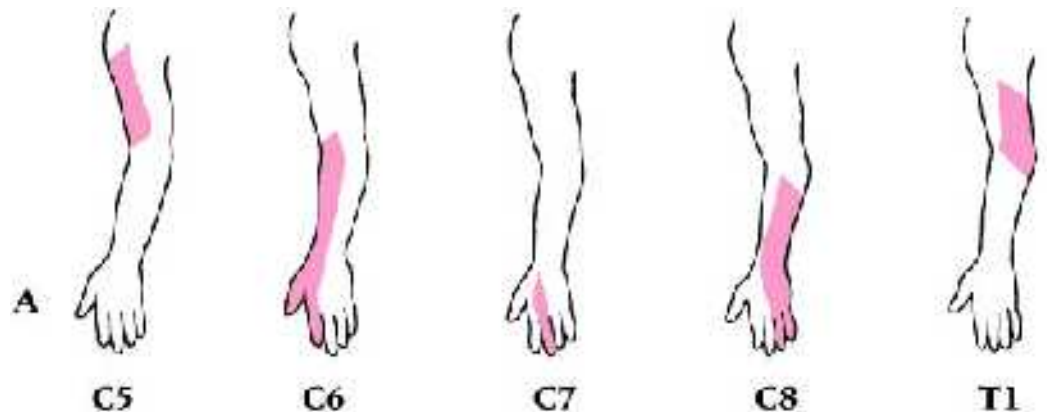
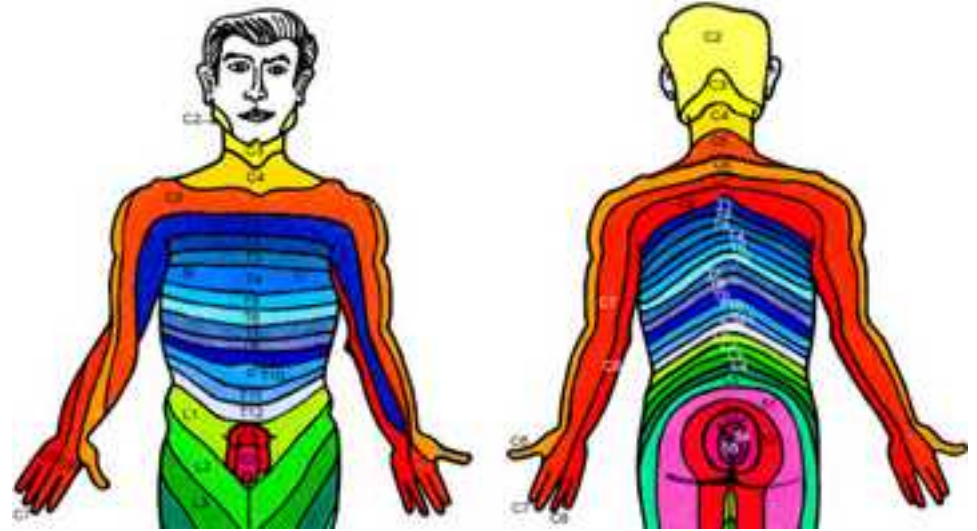
- All based upon anatomical position
- C5 – lateral arm
- C6 – lateral forearm, thumb, index finger
- C7 – posterior forearm, middle finger
- C8 – medial forearm, ring and little fingers
- T1 – medial arm

Brachial Plexus - Myotomes

- Minor differences will exist from one resource to another
- C5 – shoulder abduction
- C6 – elbow flexion or wrist extension
- C7 – elbow extension or wrist flexion
- C8 – grip strength (shake hands)
- T1 – interossei (spread fingers)

Neurological Testing

- Dermatomes
- Reflexes
 - Babinski
 - Oppenheim
 - Biceps
 - Brachioradialis
 - Triceps
- Myotomes



Brachial Plexus – Reflex Tests

- C5 – biceps brachii reflex (anterior arm near antecubital fossa)
- C6 – brachioradialis reflex (thumb side of forearm)
- C7 – triceps brachii reflex (at insertion on olecranon process)

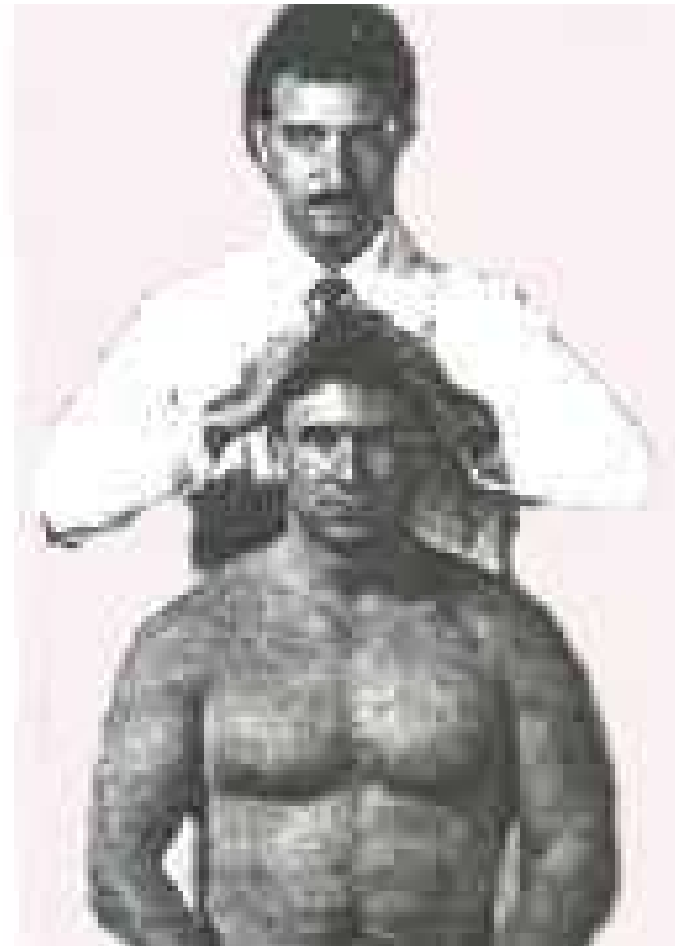
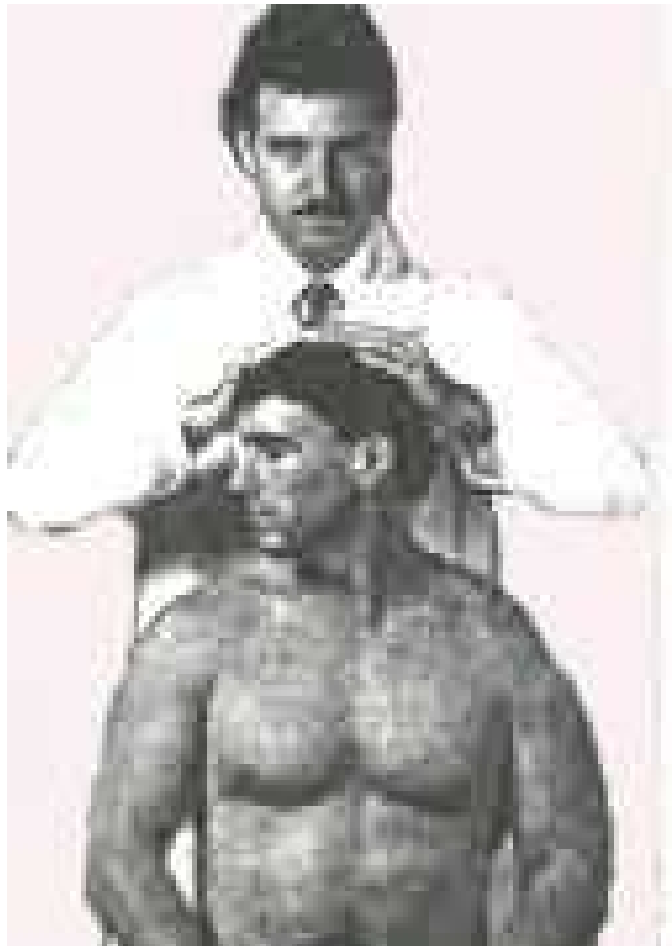
Brachial Plexus Traction Test

- Mimics mechanism of injury
- Cervical spine laterally flexed and opposite shoulder is depressed
- Positive if radiating/”burning” pain in upper extremity
 - If traction injury, symptoms noted on side of depressed shoulder
 - If compression injury, symptoms noted in direction of lateral flexion

Cervical Distraction/Compression Tests

- Distraction
 - Patient supine, clinician stabilizes head
 - Passive traction force applied to cervical spine
 - Positive test if neuro symptoms and/or pain reduced with traction force
- Compression
 - Patient sitting, clinician pushes down on top of patient's head
 - Positive test if pain and/or neuro symptoms reproduced in cervical spine and/or upper extremity

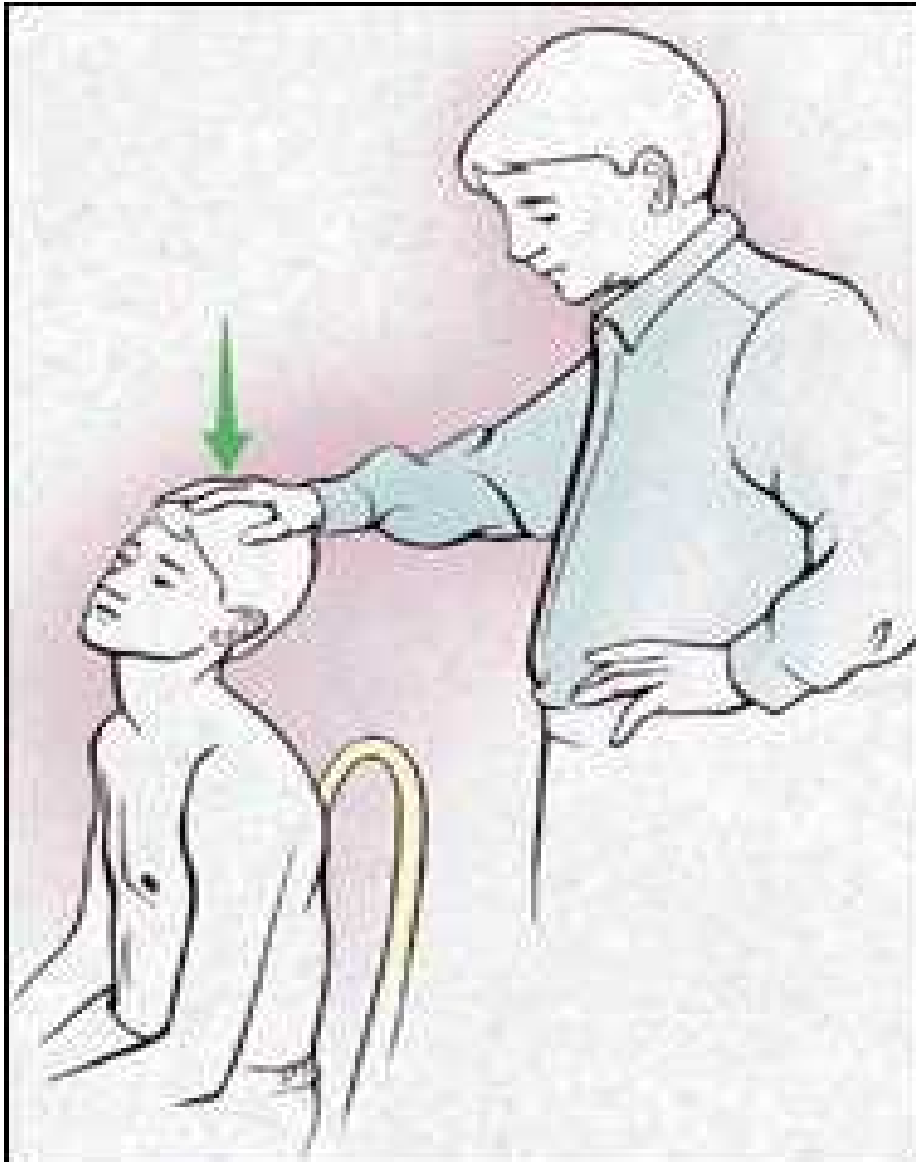
Cervical Compression Test



Spurling Test

- Same positioning as cervical compression test
- Instead of linear axial load through top of head, clinician extends and laterally rotates neck with compression to impinge on nerve root/s
- Positive if pain and/or neuro symptoms reproduced in cervical spine and/or upper extremity

Spurling Test

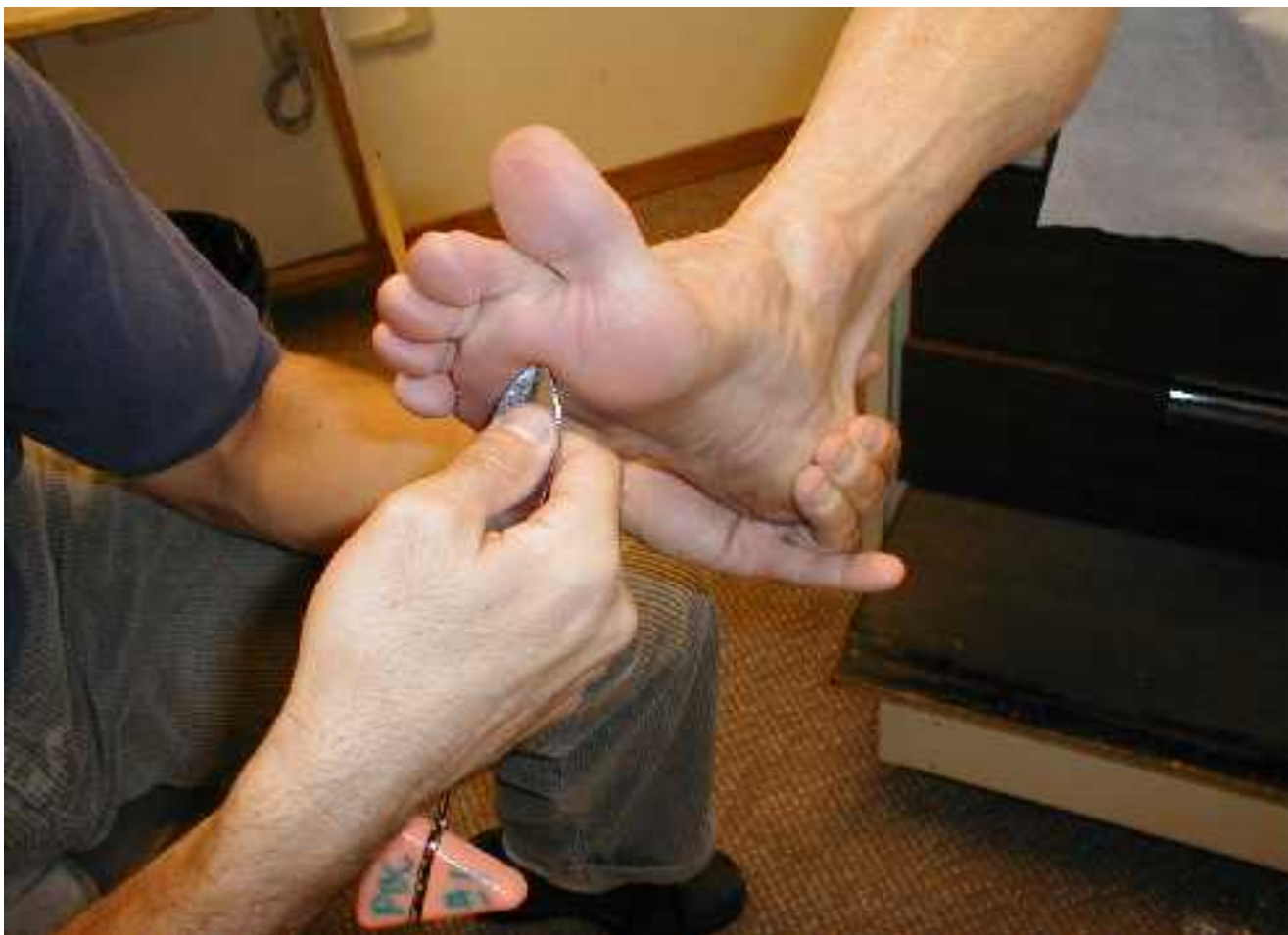

© 2000 Marcia Harstock

Upper Motor Neuron Lesions

- Symptoms of catastrophic head and/or spinal cord injury associated with trauma
- Babinski test
 - Blunt device stroked along plantar aspect of foot from calcaneus to 1st metatarsal head
 - Positive test if great toe extends and other toes splay
- Oppenheim test
 - Fingernail ran along medial tibial border/crest
 - Positive test if great toe extends and other toes splay

Babinski Test



Vertebral Artery Test

- Assesses patency of vertebral artery
- Patient placed supine on table
- Clinician supports head at occiput
- Patients neck passively extended, laterally flexed and then rotate toward laterally flexed side for ~30 seconds
- Positive test if dizziness, confusion, nystagmus, unilateral pupil changes and/or nausea present

Cervical Spine Pathologies

Cervical Spine Injuries

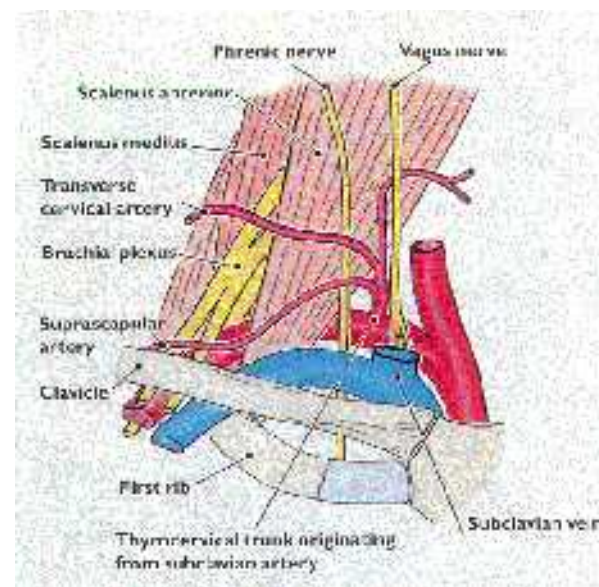
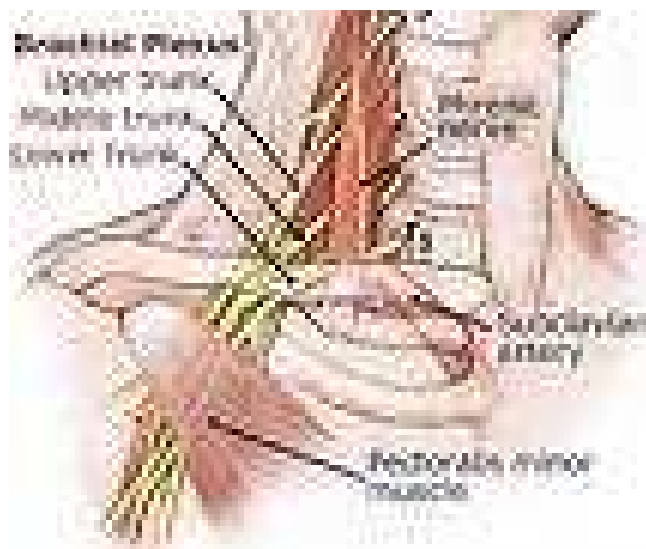
- Acute injuries typically trauma induced and involve excessive movement/s of the spine and injury to related structures
- Chronic conditions result from poor posture, muscle imbalances, decreased flexibility and/or repetitive movement related to activity

Cervical Spine Injuries

- Brachial plexus injuries (stinger/burner)
 - Compression or distraction
- Cervical nerve root impingement
 - Degenerative disc changes
 - Acute disc injury
- Sprain/strain syndrome
 - Difficult to differentiate
- Vertebral artery impingement

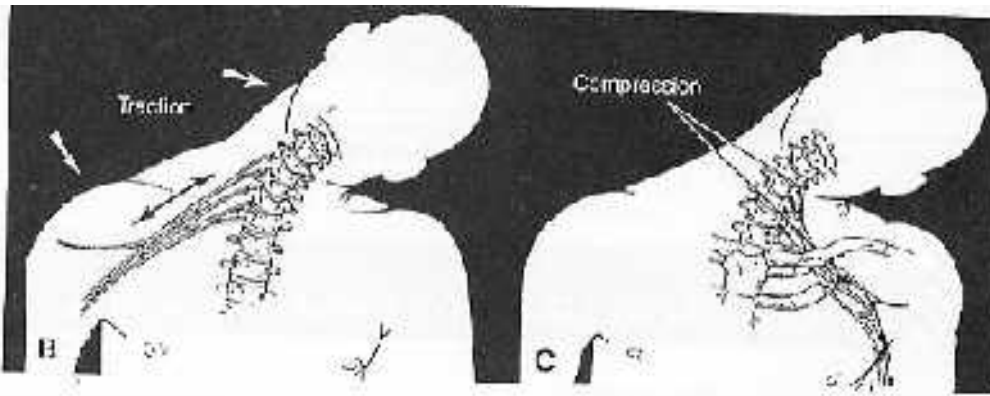
Cervical Injuries

- Brachial Plexus (C5-T1) “burners or stingers”
 - MOI: stretch or compression
 - S/S: burning or stinging neck/arm/hand, muscle weakness, supraclavicular tenderness (Erb’s Point), neck pain
 - chronic: numbness ,tingling, and weakness lasts longer



Brachial Plexus Pathology

- Neurological findings!!



- Burning, achy pain
- Muscle weakness
- Point tenderness
- Mechanism of Injury

TESTS:

- Brachial Plexus Traction Test
- Tinel's Sign
- Spurling's Test
- Cervical Distraction

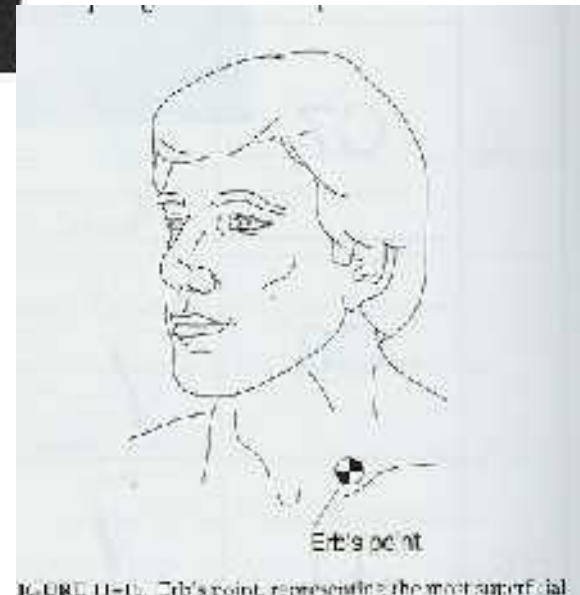

FIGURE 11-10 Erb's point, representing the most superficial

Brachial Plexus Injury

- Compression force – nerve roots pinched between adjacent vertebrae
 - Increased risk if spinal stenosis (narrowing of intervertebral foramen) exists
- Distraction force – tension or “stretch” force on nerve roots
 - Most common at C5/C6 levels but may involve any cervical nerve root
 - Erb’s point – 2-3 cm above clavicle anterior to C6 transverse process, most superficial passage of brachial plexus

Erb's Point



Brachial Plexus Injury

- Signs and symptoms
 - Immediate and significant pain
 - “Burning” or radiating pain in upper extremity
 - Dropped shoulder on affected side
 - Myotome and dermatome deficiencies at affected nerve root levels
- Generally, symptoms minimize or resolve quickly
- If recurrent, takes less trauma to induce symptoms and longer for symptoms to diminish

Cervical Nerve Root Impingement

- Disc related conditions
 - Degenerative disc changes
 - Disc herniations – most at C5/C6 or C6/C7 levels
 - Often presents with head in position of least compression on affected nerve root/s
 - Similar neuro symptoms to brachial plexus injuries at involved level/s
- Narrowing of intervertebral foramen
 - Exostosis (bone spur)
 - Facet degeneration

Cervical Nerve Root Impingement

- Causes:
 - Spinal stenosis
 - Disc herniations (C5-6 or C6-7) are most common
 - Chronic Muscular Tension/Facet Joint Syndrome
- Pain characteristics:
 - Radiating pain into upper extremity
- Upper quarter screening reveals:
 - Sensory deficits and/or muscle weakness

Sprain/Strain Syndrome

- Since unable to directly palpate facet joints, difficult to differentiate pain/spasm associated with sprain of joint capsule from strain of musculature
- Inflammation from sprain/strain may irritate nerve roots in close anatomical orientation to affected area and produce neuro symptoms
- Severe sprains (dislocations) will present with postural change due to joint disassociation

Cervical Strains and Sprains

- S/S:
 - limited AROM/RRROM/PROM,
 - diffuse tenderness,
 - no peripheral pain or paresthesia,
 - **normal neurological**
- To Board or Not to Board – That is the question?
- **Criteria for return to play
 - Full pain free ROM and strength, Dr. approval

Vertebral Artery Impingement

- Due to anatomic location, may be compromised with same mechanism of injury as brachial plexus/cervical nerve root impingement injuries
- Signs and symptoms
 - Dizziness
 - Confusion
 - Nystagmus

Cervical Disk, Nerve Impingement, or Fracture/Dislocation

- S/S:
 - **Abnormal neurological**
 - **Peripheral pain or paresthesia,**
 - specific tenderness
- BOARD them and call 911
- **Criteria for return to play
 - Full pain free ROM and strength, Dr. approval

Cervical Facet Joint Syndrome

- S/S:
 - limited AROM/RRROM/PROM,
 - Achy and intermittent pain – relieved by position changes,
 - **peripheral pain or paresthesia is unlikely,**
 - **normal neurological**
 - **unless chronic and symptoms have developed**
 - ****Criteria for return to play - Full pain free ROM and strength, Dr. approval**

Neck Injuries

- Contusions to Neck
 - MOI: Clotheslining
 - Voice box injury, Tracheal injury
 - Loss of voice, Raspy voice
 - Inability to swallow